



# Characterization of soft and hard tissue lesions in an oral medicine unit in the central region of Portugal: a 5-year retrospective study

Camila Trimboli<sup>1</sup>, Tiago Marques<sup>2</sup>, Raquel Silva<sup>2</sup>, Nélio Veiga<sup>2</sup>, Patrícia Couto<sup>2</sup>

1- Faculdade de Medicina Dentária, Universidade Católica Portuguesa, Viseu, Portugal  
 2- Centre for Interdisciplinary Research in Health, Universidade Católica Portuguesa, Viseu, Portugal

## Background

The present study aims to assess the prevalence of different types of soft and hard tissue lesions diagnosed through anatomopathological examination, in a sample from the central region of Portugal; to analyze the risk factors associated with these lesions; as well as the prevalence of malignant neoplasms.

## Materials and methods

A search of the anatomopathological records of soft and hard tissue lesions was carried out, between January 2017 and December 2021. The following variables were analyzed: gender, age at the time of biopsy, exposure to risk factors, anatomical location, and the prevalence of malignant neoplasms. All data were anonymized and kept confidential throughout the investigation, being for the exclusive use of the research team.

## Results

52 biopsies were performed. The most diagnosed pathology was fibroma, followed by epulis (Fig.1). The gender most affected was the female with 59.62% and the mean age of patients was 56.54 years (Fig.2-3). Smoking habits and the use of ill-fitting dentures were the most common risk factors among the patients (Fig.4). The prevalence of malignant neoplasms was 5.77%, with a higher incidence among females (3.85%) and in the age group between 71-80 years (3.85%) (Fig.2-3).

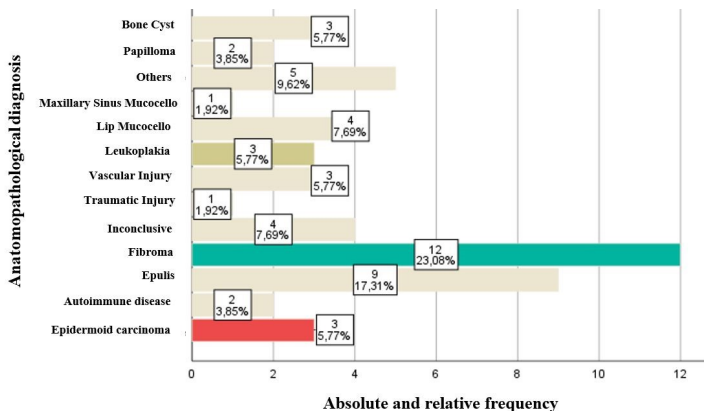


Fig.1. Distribution by frequency of oral lesions diagnosed through anatomopathological examination. **Others\*** - refers to amalgam tattoo; median rhomboid glossitis; epithelial hyperplasia; lipoma; drug reaction. **Autoimmune Disease#** refers to Erosive Lichen Planus and Bullous Pemphigoid.

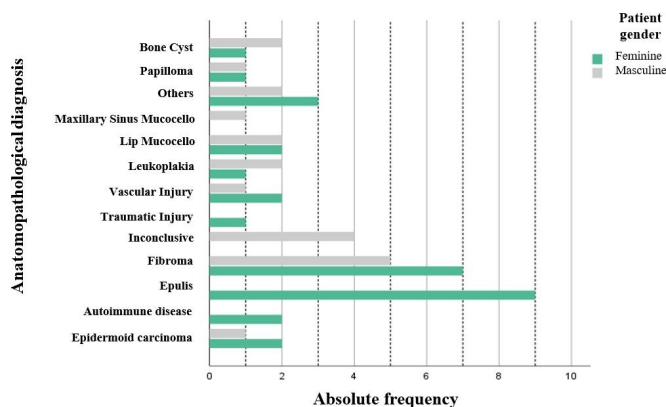


Fig.2. Distribution of lesions diagnosed by gender of patients undergoing biopsy.

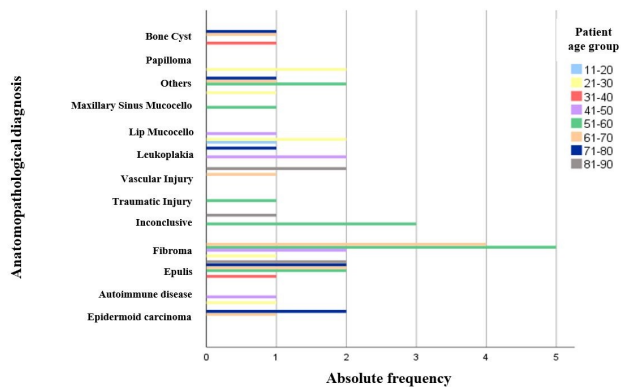


Fig.3. Distribution of lesions diagnosed by age.

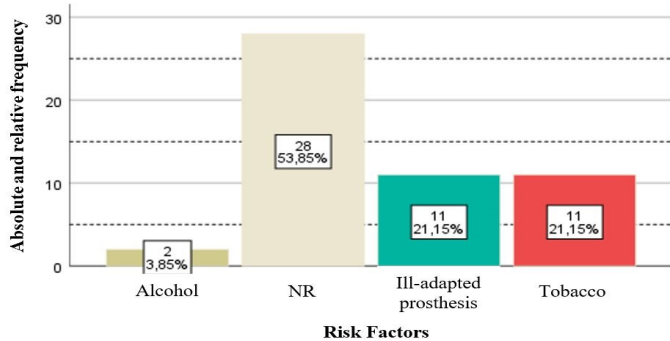


Fig.4. Distribution of patients who presented risk factors in the clinical history.

## Conclusions

The various lesions diagnosed confirm that biopsy followed by anatomopathological examination is a highly relevant procedure, together with clinical examination and a detailed anamnesis, to obtain an accurate and definitive diagnosis of oral cavity lesions.