UNIVERSIDADE CATÓLICA PORTUGUESA

VISEU

Correlação tomográfica e topográfica do trajeto anatômico do nervo alveolar inferior e a osteotomia sagital do ramo mandibular

Dissertação apresentada à Universidade Católica Portuguesa
para obtenção do grau de Mestre em Medicina Dentária

Por:
Alessandro Costa da Silva

Viseu, 2020

UNIVERSIDADE CATÓLICA PORTUGUESA

VISEU

Correlação tomográfica e topográfica do trajeto anatômico do nervo alveolar inferior e a osteotomia sagital do ramo mandibular

Dissertação apresentada à Universidade Católica Portuguesa
para obtenção do grau de Mestre em Medicina Dentária

Por:
Alessandro Costa da Silva

Orientador: Profa. Doutora Susana Silva
Coorientador: Prof. Doutor Adriano Rocha Germano

Viseu, 2020

“ Você não precisa acreditar no impossível, você só precisa ter fé e acreditar em Deus. Assim, TUDO é possível*”*.

Autora: Carolina Bensino

AGRADECIMENTOS

DEUS

A Deus por todas as bençãos derramadas em minha vida profissional e pessoal

FAMILIA

O motivo de todo o esforço e empenho

Em especial a minha amada esposa Patrícia que participou comigo desse projeto me dando todo a tranquilidade necessária em todos os momentos para que esse curso fosse concluído

A PROFESSORA DRA. SUSANA

Pelo acolhimento, solicitude e orientação assertiva na elaboração desse trabalho

AO PROFESSOR E AMIGO ADRIANO ROCHA GERMANO

Pela sincera amizade ao longo desses anos, me sinto abençoado por tê-lo como amigo

AO AMIGO JOÃO CARLOS AMORIM LOPES

Pela solicitude em todos os momentos e pela sincera amizade desenvolvida ao longo deste curso que com certeza perdurara pela vida

AOS COLEGAS DO CURSO DE MEDICINA DENTÁRIA

Pelos bons momentos que passamos e pelo companheirismo mútuo de todos ao longo do nosso curso. Uma amizade que permanecerá apesar da distância

À UNIVERSIDADE CATÓLICA DE VISEU

Pela oportunidade que me concedeu em continuar meus estudos e por abrir novos horizontes em minha carreira profissional

RESUMO

Introdução: Este estudo teve por objetivo avaliar a correlação topográfica do trajeto do nervo alveolar inferior com o seu posicionamento intraoperatório após separação dos cotos osteotomizados na osteotomia sagital do ramo mandibular em pacientes com deformidade dentofacial.

Materiais e Métodos: Um estudo prospectivo e de secção transversal foi conduzido através da análise de 20 indivíduos portadores de deformidades dentofaciais que foram submetidos a osteotomias sagitais do ramo mandibular bilateralmente. As análises consistiram em medidas da distância do nervo alveolar inferior a córtex óssea lingual e bucal, a mensuração da espessura mandibular, grau de densidade óssea mandibular (unidades de Hounsfield) e a proporção de osso cortical e medular em três locais diferentes. Durante o período intraoperatório, foi analisado o segmento ao qual o nervo permaneceu aderido após a realização da osteotomia sagital do ramo sagital mandibular, e esses dados foram correlacionados.

Resultados: A distância medida do canal mandibular à superfície interna do osso cortical vestibular mostrou um valor médio de 2,6 mm no ponto "A" quando o nervo permaneceu aderido ao segmento distal e valor médio de 0,7 mm quando o nervo foi aderido no segmento proximal . Quanto à espessura, o valor médio foi de 11,2 mm no ponto "A", quando o nervo aderiu nos segmentos distais e 9,8 mm no ponto "A", quando aderido no segmento proximal. Após a avaliação tomográfica de 40 hemi-mandíbulas, observou-se que houve uma relação significante ($p<0,05$) entre a espessura do corpo mandibular, e a distância do trajeto do nervo alveolar inferior à córtex vestibular e lingual com a possibilidade de seu encarceramento intra-operatório durante a osteotomia sagital do ramo mandibular.

Conclusão: Este estudo concluiu que mandibulas que apresentavam o corpo mandibular estrreito e com a distância do trajeto do nervo alveolar inferior a superfície interna das corticais linguais e vestibulares menores que dois milímetros aumentavam significativamente o risco do encarceramento do nervo alveolar inferior durante a osteotomia sagital do ramo mandibular.

Palavras Chave: Osteotomia sagital do ramo mandibular; Nervo alveolar inferior; Deformidades dentofaciais, Parestesia, Tomografia computadorizada

ABSTRACT

Introduction: This research evaluated the topographic correlation, through computed tomography (CT Scan), of the trajectory of the inferior alveolar nerve with its intraoperative positioning after mandibular sagittal split osteotomy in patients with dentofacial deformities.

Material and Methods: A prospective cross-sectional research was carried out through the analysis of twenty CT scans of individuals with dentofacial deformities who underwent mandibular bilateral sagittal split osteotomy (BSSO). The analyzes consisted of measurements of the distance from the inferior alveolar nerve to the lingual and buccal bone cortex, the mandibular thickness measurement, the degree of mandibular bone density (Hounsfield units) and the proportion of cortical and medullary bone in three different locations. During the intraoperative period, the segment to which the nerve remained adhered after performing mandibular sagittal split ramus osteotomy was analyzed, and these data were correlated.

Results: The distance measured from the mandibular canal to the internal surface of the buccal cortical bone showed a mean value of 2.6 mm at point "A" when the nerve remained adhered the distal segment and mean value of 0.7 mm when the nerve were adhered in proximal segment. As for the thickness the mean value was 11.2 mm at point "A", when the nerve adhered in distal segments and 9.8 mm at point "A", when adhered in proximal segment. In the 40 osteotomies evaluated, the mandibular thickness, distance from the mandibular canal to the buccal cortical bone and distance from the mandibular canal to the lingual cortical bone were observed to be significantly related to the intraoperative position of the inferior alveolar nerve ($p<0,05$).

Conclusion: This study concluded that mandibles that presented a narrow mandibular body and with a reduced distance of the inferior alveolar nerve trajectory to the internal surface of the lingual and vestibular cortical bone less than two millimeters have significantly increased the risk of nerve entrapment during mandibular sagittal split ramus osteotomies.

Key Words: Mandibular bilateral sagittal split ramus osteotomy, Inferior alveolar nerve, Dentofacial deformities, Paresthesia, Computed tomography.

ÍNDICE

I. INTRODUÇÃO **4**

II. ARTIGO CIENTÍFICO **9**

III. NORMAS PARA A PREPARAÇÃO DO ARTIGO CIENTÍFICO **34**

IV. CONCLUSÃO **51**

V. BIBLIOGRAFIA **55**

VI. ANEXOS **63**

6.1 Anexo A – Comprovação de Submissão do Artigo Científico **63**

6.2 Anexo B - Declaração de Cumprimento Antiplágio **64**

6.3 Anexo B - Declaração do Comitê de Ética em Pesquisa **65**

I. INTRODUÇÃO

I. INTRODUÇÃO

É possível encontrar na literatura diferentes modelos de osteotomias mandibulares para a correção de deformidades dentofaciais. No entanto, a mais frequente, conforme Tsuju e colaboradores em 2005, é a osteotomia sagital do ramo mandibular especialmente por sua condição de poder ser utilizada em diferentes situações clínicas como, por exemplo, nas assimetrias, nos avanços e nos recuos mandibulares.

Trata-se de uma cirurgia que, de um lado, apresenta uma grande versatilidade, por outro, pode levar a complicações de variados graus no intraoperatório bem como no pós-operatório. Como vantagem podemos considerar a flexibilidade no reposicionamento do segmento distal osteotomizado, as leves alterações no posicionamento muscular e articular da mandíbula e um contato ósseo apropriado após o reposicionamento dos cotos osteotomizado (AIZENBUD e colaboradores em 2012; YOUNG-KYUN e colaboradores em 2010).

Dentre as possíveis intercorrências durante a OSRM a mais frequentes é o encarceramento do nervo alveolar inferior (NAI) no segmento proximal ou distal após a separação dos cotos fraturados na OSRM. E, como consequência, a complicação mais comum após esse procedimento é a parestesia do NAI, que devido a sua trajetória, apresenta-se predisposto a sofrer lesões que podem ser transitórias ou definitivas (SOUZA e colaboradores em 2012, AIZENBUD e colaboradores em 2012).

A incidência da parestesia do nervo alveolar inferior após a osteotomia sagital do ramo mandibular varia acima da metade de todos os casos, chegando em alguns estudos ate 100% dos casos no pós-cirúrgico imediato. Embora possa ser provocada por diferentes causas, as parestesias pós-cirúrgica mais frequente são causadas principalmente por duas etiologias: o afastamento medial do nervo alveolar inferior antes de sua entrada no canal mandibular e a manipulação do nervo durante abertura das osteotomia mandibulares. Essas lesões neurológicas podem ocorrer em diversas etapas durante o procedimento cirúrgico quer seja pelo uso de serras, cinzéis, afastadores, parafusos de fixação ou simplesmente durante a separação da osteotomia sagital do ramo mandibular, sendo esta a etapa mais crítica com relação aos danos do nervo mandibular (YLIKONTIOLA e colaboradores em 2000; TEERIJOKI-OKSA e colaboradores em 2002; PANULA e colaboradores em 2004; YOSHIOKA e colaboradores em 2010).

A falta ou diminuição de sensibilidade também conhecida como parestesia, tem sua alta prevalência com a utilização dessa técnica devido ao trajeto interno na mandibula que esse nervo percorre e a correlação sua com a osteotomia sagital da mandíbula. Para que essas lesões sejam minimizadas é sempre preferível que o nervo permaneça aderido ou totalmente incorporado no segmento distal mandibular para que seja minimamente manipulado e por consequência sofra um menor distúrbio neurosensorial pós-operatório (FRIDRICH e colaboradores em 1995). O nervo ainda pode sofrer, além das manipulações intraoperatórias, uma compressão pós-operatória pela formação exacerbada de edema ou hematoma próximo à entrada do canal mandibular, causando assim distúrbios na sua condição nervosa e, por consequência, parestesia (YOUNG-KYUN e colaboradores em 2010).

De acordo com um estudo realizado em 2012, Aizenbud e colaboradores verificaram que o minucioso conhecimento pré-operatório da localização topográfica do NAI e a sua trajetória dentro da mandíbula, por meio da tomografia computadorizada, é de suma importância para diminuir a incidência das lesões neurológicas pós-operatórias. Através do prévio conhecimento do trajeto do NAI no interior da mandibula, é possível estimar o risco de parestesia pós-operatória e definir estratégias para minimizar esses danos (YU & WONG em 2008; NOLETO e colaboradores em 2010). Devido à alta prevalência dessas complicações, esse tema vem sendo abordado em diversos estudos na literatura internacional (FRIDRICH e colaboradores em 1985; TSUJI e colaboradores em 2005). No entanto, a correlação do posicionamento tomográfico do NAI e a incidência do seu encarceramento intraoperatório não têm sido objeto de interesse nas pesquisas recentes.

Por essa razão, o foco deste estudo é relacionar o posicionamento topográfico do NAI por meio de tomografias computadorizadas e sua posição intraoperatória após a divisão dos segmentos ósseos na OSRM bilateralmente.

II. ARTIGO CIENTÍFICO

II. ARTIGO CIENTÍFICO

1. Introduction

Bilateral sagittal osteotomy of the mandibular ramus is the procedure most frequently used for correcting dentofacial deformities of the mandible due to its versatility, because it may be used in both cases of mandibular advancement and setback, as well as in mandibular asymmetries[1].

This type of osteotomy has various advantages, such as great flexibility with regard to repositioning the distal segment, good bone contact after repositioning of the segments, and minimal changes in the position of temporomandibular muscles and joints[2,3].

Some complications may occur after mandibular sagittal split ramus osteotomy, among these, the most prevalent is paresthesia of the inferior alveolar nerve due to its intraosseous trajectory and the relationship of surgical site. Because of all these characteristics, the nerve runs great risk of suffering either temporary or permanent injuries[2,4]. This nerve disturbance ranges from 50% to 100%[5,6] in the immediate post-operative period. According to Hanzelka *et al*. (2011)[7], the two main causes of post-operative paresthesia may be: 1) Medial retraction of the extraosseous portion of the inferior alveolar nerve at the time of horizontal osteotomy of the mandibular ramus[8,9] and 2) Manipulation or damage of the inferior alveolar nerve during the osteotomies, which is usually caused by use of the saw, chisels, retractors, retention screws, and during the split of the mandibular ramus, which lastly, is the most critical stage with regard to damage to the inferior alveolar nerve. The intraoperative position of the nerve and degree of manipulation are strictly correlated with post-operative neurosensory disturbance, therefore, it is preferable for the nerve to remain adhered to the distal segment as long as possible[1,3]. Young-Kyun *et al.* (2010)[3], have also cited hematoma and/or edema formation close to the mandibular and menton foramens as another source for inferior alveolar nerve paresthesia.

According to Aizenbud *et al*., (2012)[2] the preoperative knowledge of the anatomic location and course of the inferior alveolar nerve, by means of CT scan is essential for reducing complications related to nerve damage. The measurement of this relationship is important to enable surgeons to correlate the mandibular canal anatomy to the design of the osteotomies and thus aim to prevent or reduce the incidence of postoperative paresthesia. Some researchers have investigated this relationship, however, the correlation of the nerve

anatomy (by means of CT scan) and the intraoperative findings (such as nerve entrapped inside the bone segments) are scarce in the literature[1,10,11,12].

The aim of this study was to evaluate the relationship the anatomic position of the mandibular canal (by means of CT scan) and the intraoperative position of the inferior alveolar nerve after mandibular sagittal split ramus osteotomy.

2. Methodology

The participants in this prospective, cohort study were 20 patients with dentofacial deformities, who were submitted to orthognathic surgery that involved bilateral mandibular sagittal split ramus osteotomy, and were treated by the Residency Program in Oral and Maxillofacial Surgery and Traumatology of the "Hospital Universitário Onofre Lopes" of the Federal University of Rio Grande do Norte (UFRN) in the period between September 2013 and December 2014.

Those included in this study were patients with dentofacial deformities, with indication for orthognathic surgery including bilateral mandibular sagittal split ramus osteotomy according to the technique of Trauner and Obwegeser (1957)[13], modified by Dal Pont (1961)[14] and Hunsunck (1968)[15]. Patients were classified as ASA I and II **(***American Society of Anesthesiologist (ASA)* and also classified as Goldman Class I and II.

Excluded from this study, were claustrophobic patients and/or severely obese patients (weighing over 350 lb), due to the need to be submitted to preoperative CT scan in a hospital facility. Patients classified as ASA III, IV and V, and Goldman Class III and IV were also excluded from this study due to the risks inherent to general anesthesia.

The research was approved by the Ethics Committee, in Report Number: 379,988 (Attachment I). In order to be included in this research, all the patients signed the term of free and informed consent and underwent to computed tomography imaging exams of the mandible in the preoperative period. The patients were also registered in a standardized research form that contained some general data, such as: name, age, sex, race, address and professional occupation. Tomographic anatomy of the mandibular ramus, type of dentofacial deformity, type of orthognathic surgery planned and any uneventful intraoperative event regarding mandibular osteotomy technique (amount of mandibular advancement or setback, unfavorable mandibular fracture, neurovascular bundle section and whether or not the bundle nerve remained adhered to the proximal segment of the sagittal osteotomy) were recorded (Attachment II).

The analyses were made by means of helicoidal computed tomography (Phillips Brilliance CT - 64 channels) with slice thickness of 1 mm, reconstruction interval of 1mm, bone (enhancement) filter, FOV of 16 cm – vertex/suprahyoid, or cone beam CT scan (I-cat, Imaging Sciences International), with slice thickness of 0.3 mm, without intravenous contrast injection. After capturing the axial images, the native images were saved in

universal DICOM format and transmitted via transmission control protocol in an Gigabit Ethernet network environment to the tomographic console located in a contiguous hospital room. The original data of the CTs were stored in a removable media (CD/DVD-ROM) for posterior reading and analysis at an independent work station. For measurement of the distances, graphic computation tools would be used to obtain the para-sagittal/coronal views. Analysis of the bone area and density were made by means of calculating the ROIs within the respective reference lines traced. For this effect, the Osirix 5.0.2 Software (Macintosh Platform– OSX Mountain Lion) was used.

The mandibular thickness measurements, distance from the internal aspect of its vestibular and lingual cortical bones in relation to the mandibular canal (Fig.1), as well as the measurements of the medullary/cortical bone proportion and density, measured in Hounsfield Units (Fig.2) were taken in three different points of the mandible, by means of transversal/coronal views of the computed tomography images, and were based on some guidelines. Line "A" that passes in the region of the second molar furca, and is parallel to the long axis of the mandibular second molar, and Line "B" found in the region corresponding to the furca of the third molar, and is parallel to the long axis of the mandibular second molar. The points evaluated were situated in the area of the intersection lines with the mandibular canal as follows: "A" is localized at the intersection of line "A" with the mandibular canal; point "B" at the intersection of line "B" with the mandibular canal. In addition to these, a third point (C) was evaluated. This point was situated in the region immediately anterior to the mandibular lingual, when the mandibular canal was found to be completely corticalized (in the computed tomography image), as shown in the Figure below (Figure 3). The evaluations were made in the 3 points in isolation, and at the points in conjunction, by using the formula "(A + B + C)/3".

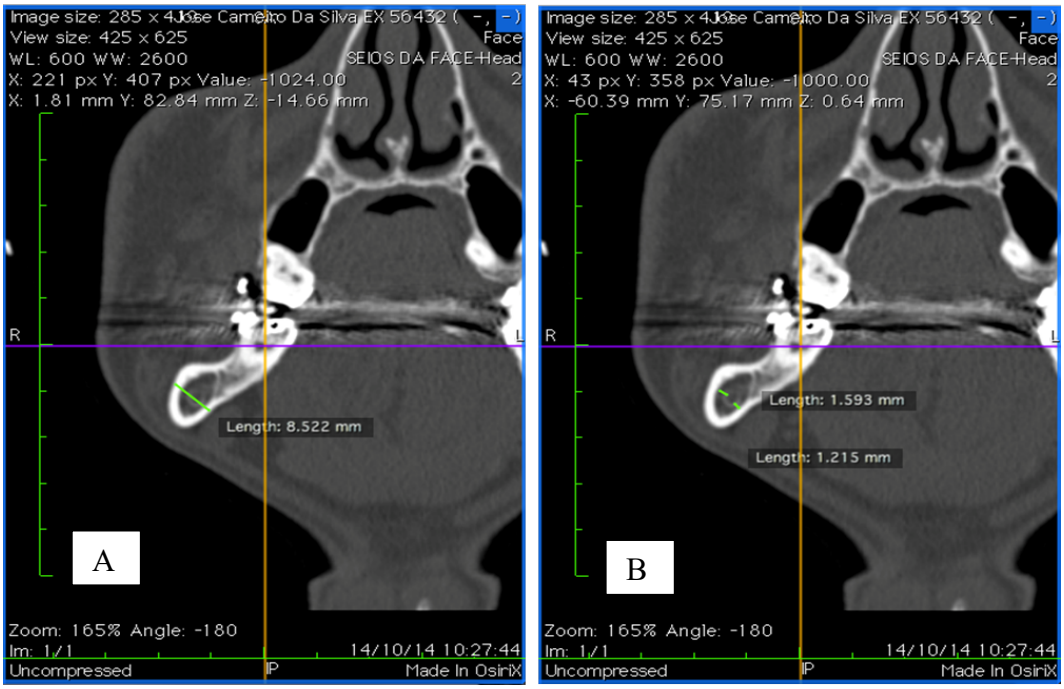

Figure 1: A – Transverse mandibular body distance B- Distance from the inferior alveolar nerve to the internal surface of the buccal cortical bone and measured from the distance of the mandibular canal to the internal surface of the lingual cortical bone.

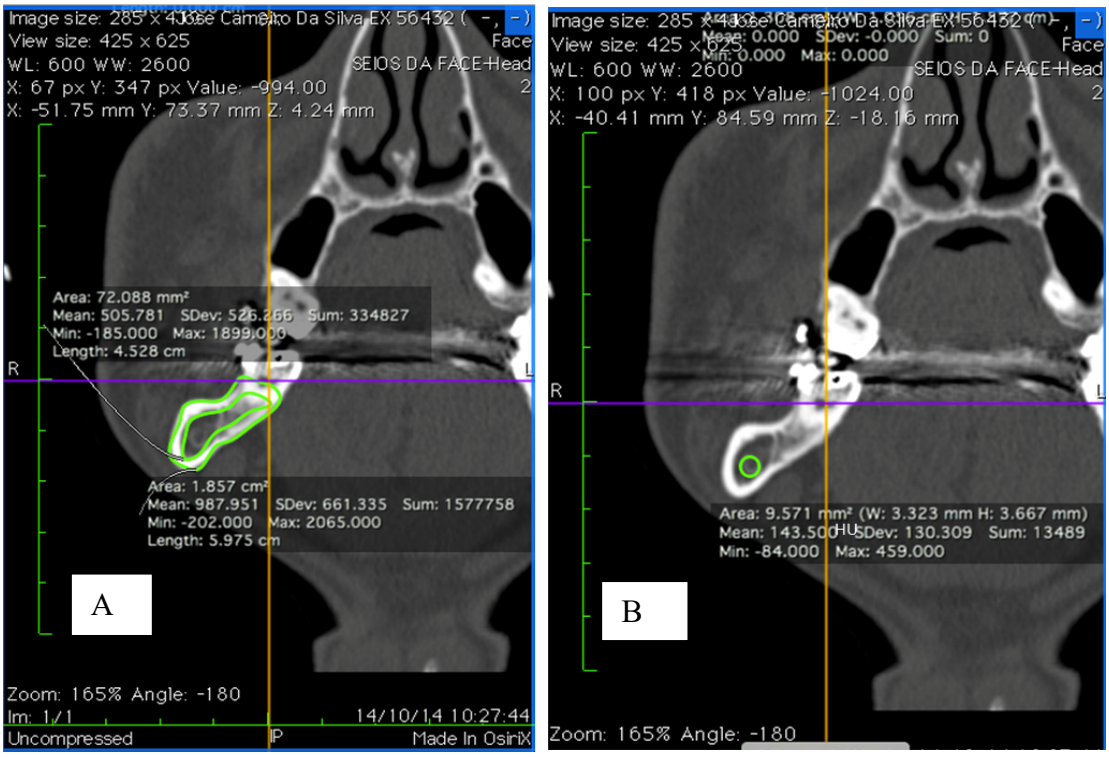

Figure 2: A- Evaluation of the area of the cortical and medullary bone B- Area of bone density evaluation (Hounsfield Units)

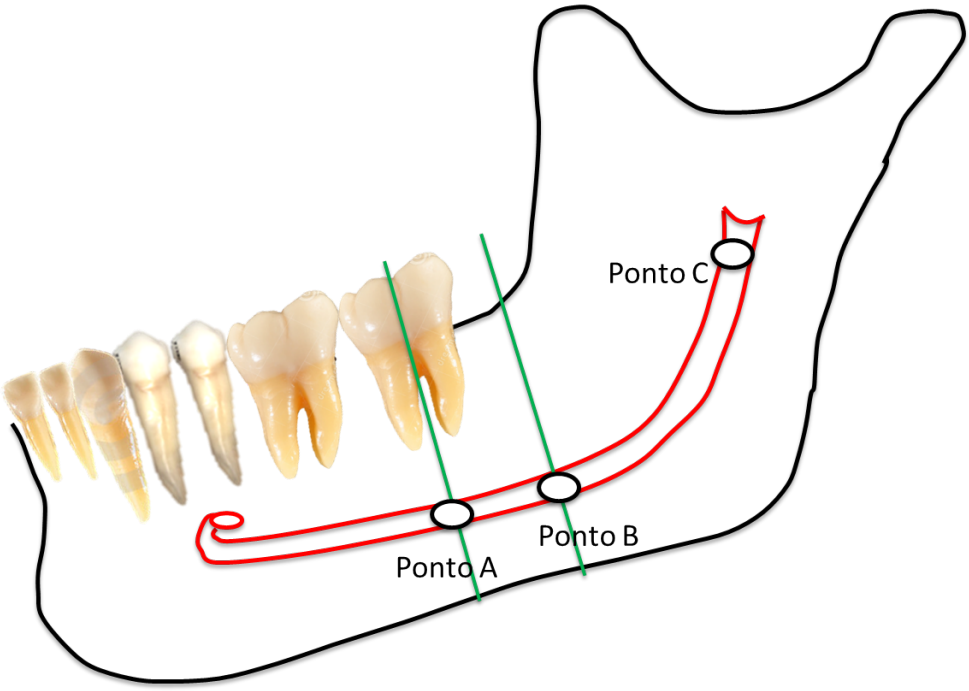

Figure 3: Points used for evaluating the variables in the computed tomography image

Measurement of the cortical and medullary bone proportion was made from the absolute measurements of the cortical and medullary areas in mm^2 and with these data. The simple rule of three was used to obtain the proportion of cortical and medullary bone at each point evaluated and in the three points in conjunction.

All the radiographic measurements were made 3 times, by a single, previously calibrated examiner, by visualization and diagnosis in computed tomography images, independently, with an interval of 5 days between measurements, in a room with a controlled light and free of external stimuli. Afterwards the means of the 3 measurements made were obtained.

The intraoperative position of the inferior alveolar nerve bundle after mandibular sagittal split ramus osteotomy was divided into two possible sites: 1- distal segment; 2- proximal segment. The nerve was classified as being present in the distal segment when it fitted in with the type I and II classifications of Hanzelka *et al.* (2011), and did not require surgical manipulation; it was classified as being in the proximal segment when it fitted in with the Types III and IV, therefore, requiring manipulation of the nerve during the surgical procedure.

Data analysis was performed with the *SPSS software (Statistical Package for Social. Sciences)* for *Windows*, version 22. Descriptive analysis of the data verification of normality were performed. Assuming normality and independence of the sample, the Student's-*t* test was performed to verify significant difference. To verify significant association, the Pearson Chi-square and Exact Fisher tests were used. Values of $p<0.05$ were considered significant.

3. Results

The participants in this research were twenty patients with dentofacial deformities, of whom eleven were female (55%) and nine were male (45%), with a mean age of 23 years old ranging between 17 and 40 years.

Among the twenty patients observed, two were submitted to only mandibular bilateral sagittal split osteotomy (BSSO), twelve were submitted to BSSO and Le Fort I osteotomy and six patients were submitted to BSSO, Le Fort I osteotomy and mentoplasty.

3.1 Relationship between the inferior alveolar nerve topography and patients' gender (Tables 1)

When the female gender was evaluated in isolation, a total of 22 sagittal split osteotomies were verified; in 13 (59%) the nerve was shown to be adhered to the distal segment, and in 9 (41%) to the proximal segment. Whereas in the male gender, out of a total of 18 sagittal split osteotomies, the nerve remained adhered to the distal segment in 13 (72.2%) and in the proximal segment in 5 (27.8%).

The measurements of distance from the mandibular canal to the buccal cortical bone at points "A", "B" and "C" in patients of male gender were: 2.6 mm, 1.4 mm and 0.5 mm, respectively. The measurements obtained at points "A", "B" and "C", in patients of the female gender were: 1.4 mm, 0.7 mm and 0.6 mm, respectively, demonstrating higher mean values for the male sex, with statistical significance ($p<0.05$) at point "A" when evaluated in isolation, and in points "ABC/3" when analyzed in conjunction. The mean "ABC/3" in the male sex was 1.5 mm and in the female sex, 0.9 mm.

When the distance from the mandibular canal to the lingual cortical bone was evaluated, the highest mean values were found in patients of the female sex, with values at points "A", "B" and "C" of 0.9 mm, 0.8 mm and 0 mm, respectively. In the male sex, the mean values were: 0.4 mm, 0.3 mm and 0 mm, with no statistically significant difference at the points evaluated both in isolation and in conjunction. The mean values obtained at the points evaluated in conjunction in the male sex were "ABC/3": 0.2 mm and in the female sex, 0.6 mm.

In the evaluation of the mean bone thickness value there was no statistically significant correlation between the genders, with patients of the male sex showing values of 7.6 mm at point "C", 9 mm at point "B", and 11 mm, and at point "A". Whereas in the female sex,

the mean bone thickness at point “C” was 7.1 mm, at point “B”, 9.4 mm and at point “C”, 10.3 mm. In the evaluation of the points in conjunction “ABC/3” of the male sex the mean value was 9.2 mm, and in the female sex, it was 8.9 mm.

Another variable analyzed was the proportion of cortical/medullary bone, for which the mean values found in the female sex at points “A”, “B” and “C” were: 55% and 45%; 55% and 45%; 66% and 34%, respectively. In the male sex, the mean values were: 55% and 45%; 55% and 45%; 70% and 30%, respectively. There was no significant correlation between these variables in the analysis of the individual points or those in conjunction. In this latter analysis, the proportion of cortical/medullary bone for point “ABC/3” in the male sex was 61% and 39%, and in the female sex, 59% and 41% respectively.

The bone density in the female sex showed higher values than those in in the male sex at points “A” e “B”, however, there differences were not representative from the statistical point of view. The mean values in the male sex were 203 HU, 283 HU and 429 HU at points “A”, “B” and “C”, respectively, and in the female sex the mean values were 274 HU, 381 HU and 384 HU. In the evaluation of “ABC/3” in conjunction of the male sex the mean value was 305 HU, and in the female sex, 346 HU.

Table 1: Relationship between the inferior alveolar nerve topography and patients' gender

Variables	Male Gender			Female Gender				
	Mean (IC 95%)	S.D.	Mean	Mean (IC 95%)	S.D.	Meas.	*P*	Dif (IC 95%)
Thickness A	11.1 (10.2/12.0)	1.7	11.3	10.3(9.6-11.1)	1.6	10.5	0.174	0.7 (-0.3/1.8)
Thickness B	9.0 (8.0/10.0)	2	9.5	9.4 (8.4/10.4)	2.2	9.1	0.592	-0.3 (-1.75/1)
Thickness C	7.6 (6.8/8.3)	1.4	7.3	7.1 (6.5/7.7)	1.3	6.6	0.273	0.5 (-0.4/1.4)
Thickness ABC/3	9.2 (8.5/10.0)	1.5	9.3	8.9 (8.4/9.5)	1.2	9.1	0.542	0.2 (-0.6/1.1)
MC-BC A	2.6 (2.0/3.2)	1.2	3	1.4 (0.9/1.8)	1.0	1.1	0.001*	1.2 (0.5/2.0)
MC-BC B	1.4 (0.7/2.0)	1.3	1.3	0.7 (0.2/1.2)	1.1	0.0	0.084	0.6 (-0.09/1.4)
MC-BC C	0.5 (0.1/1.0)	0.8	0.0	0.6 (0.3/1.0)	0.7	0.5	0.732	-0.08 (-0.6/0.4)
MC-BC ABC/3	1.5 (1.0/2.0)	1	1.4	0.9 (0.6/1.2)	0.7	0.8	0.021*	0.6 (0.06/1.1)
MC-LC A	0.4 (0.07/0.8)	0.7	0.0	0.9 (0.3/1.5)	1.3	0.2	0.151	-0.5 (-1.2/0.2)
MC-LC B	0.3 (0/0.5)	0.6	0.0	0.8 (0.3/1.6)	1.4	0.0	0.089	-0.6 (-1.4/0.08)
MC-LC ABC/3	0.2 (0.09/0.4)	0.3	0.1	0.6 (0.2/1.0)	0.8	0.2	0.074	-0.3 (-0.8/0.04)
Medullary Bone A	43 (38/47)	8.0	43.0	45 (42/49)	7.0	44.0	0.274	-2.7 (-7.8/2.2)
Medullary Bone B	42 (36/48)	12.0	40.0	45 (40/47)	8.0	45.0	0.632	-1.6 (-8.1/4.8)
Medullary Bone C	30 (23/35)	12.0	27.0	34 (30/40)	10.9	34.0	0.125	-5.6 (-12/1.7)
Medullary Bone ABC3	39 (34/42)	7.9	38.0	41 (39/44)	5.7	42.0	0.123	-3.0 (-7.0/1.0)
Cortical Bone A	57 (52/61)	8.0	56.0	55 (51/58)	7.0	55.0	0.435	1.8 (-3.0/6.0)
Cortical Bone	58 (51/63)	12.0	59.0	55 (52/59)	7.0	54.0	0.587	1.9 (-4.0/8.0)
Cortical Bone C	70 (65/76)	11.0	72.0	66 (63/69)	7.0	66.0	0.169	4.1 (-1.7/10.0)
Cortical Bone ABC3	61 (57/65)	7.7.0	61.0	59 (56/61)	5.0	57.0	0.221	2.0 (-1.5/6.8)
HU A	203 (118/289)	172.0	135.0	274 (210/338)	144.0	284.0	0.166	-70 (-171/30)
HU B	283 (196/369)	173.0	274.0	381 (286/477)	215.0	375.0	0.128	-98 (-226/28)
HU C	429 (299/558)	260.0	455.0	384 (302/466)	184.0	378.0	0.539	44 (-98/187)
HU ABC/3	305 (219/391)	172.0	305.0	346 (283/409)	141.0	406.0	0.431	-41 (-142/59)

IC 95%: Lower and Upper Limit for a confidence interval of 95%; SD: Standard Deviation; Mean/Measurement: Median; Dif: Difference among the means; MC: Mandibular Canal; BC- Buccal Cortical; LC: lingual cortical; HU: Hounsfield Units

3.2 Relationship of the distance from the mandibular canal to the internal surface of the buccal cortical bone and the intraoperative position of the nerve (Table 2)

In the computed tomography image, the distance measured from the mandibular canal to the internal surface of the buccal cortical bone showed a mean value of 2.6 mm at point "A", 1.4 mm at point "B" and 0.6 mm at point "C" when the nerve remained adhered the distal segment. For the other outcome, the mean at point "A" was 0.7 mm, at point "B", 0.4 mm and at point "C", 0.5 mm. This evaluation demonstrated statistical significance at points A and B, with $p<0.01$ at point A and $p<0.05$ at point B.

The difference was also statistically significant (p<0,001), when the points "ABC/3" were evaluated in conjunction with the means of 1.6 mm and 0.6 mm for the distal segment and proximal segment, respectively.

Of the 14 osteotomies that had the nerve bundle adhered to the proximal segment, evaluated at point A, 13 (92.8%) had distances shorter than 2 mm, and 11 (78.5%) osteotomies had distances equal to or shorter than 1 mm when the nerve remained adhered to the proximal segment, with the maximum value for this measurement, in this outcome,

being 2.2 mm. To the contrary, 20 (77%) of the 26 osteotomies that had the nerve adhered to the distal segment showed distances longer than or equal to 2 mm at point "A". In this outcome, the minimum value found was 0.7 mm.

3.3 Relationship of the distance from the mandibular canal to the internal aspect of the lingual cortical bone and the intraoperative position of the nerve (Table 2)

With regard to this variable, it was observed that when the nerve remained adhered to the distal segment, the mean obtained at point "A" was 0.3 mm, at point "B" was 0.6 mm and at point "C", 0 mm; whereas when the nerve remained adhered to the proximal segment, the mean values corresponding to points "A", "B" and "C" were: 1.42 mm, 0.8 mm and 0 mm, respectively. Of the 3 points evaluated, only point "A" showed statistically significant difference with $p<0.05$.

Of the 26 osteotomies in which the nerve remained adhered to the distal segment, 23 (88;4%) showed values lower than 1 mm. When the nerve was adhered to the proximal segment (14 sides), 7 osteotomies (50%) showed values higher than 1 mm at point "A".

In this evaluation, no significant differences were found - from the statistical point of view - when points "ABC/3" were evaluated in conjunction.

3.4 Relationship between mandibular thickness and intraoperative position of the nerve (Table 2)

The patients who had the nerve adhered to the distal segment after mandibular sagittal split ramus osteotomy, were shown to have a mean (segment) thickness of 11.2 mm at point "A", 9.8 mm at point "B", and 7.7 mm at point "C" . Whereas, when the nerve was adhered to the proximal segment, the mean thickness at point "A" was 9.8 mm, at point "B", 8.2 mm and at point "C", 6.6 mm, demonstrating statistically significant difference at the 3 points evaluated in isolation ($p<0.05$).

Similarly, when this analysis was performed at the 3 points in conjunction, the difference was statistically significant with $p<0.05$, with mean value of 9.5 mm at the points "ABC/3" - distal segment, and mean value of 8.2 mm at points "ABC/3" - proximal segment.

3.5 Relationship of the proportion between cortical and medullary bone and intraoperative position of the inferior alveolar nerve (Table 2)

The percentage of cortical/medullary bone present in the CT slices evaluated represented no statistical significance for the outcome when analysis of the points "ABC/3" was performed in conjunction and in the individual mode. In this mode, the patients who had the inferior alveolar nerve adhered to the distal segment, demonstrated a mean (proportion) of cortical / medullary bone at points "A", "B" and "C" of: 55% and 45%; 55% and 45%; 67% and 33%, respectively. Whereas, when the nerve was shown to be adhered to the proximal segment, this same proportion, evaluated at the same point was: 57% and 43%; 60% and 40%; 70% and 30%, respectively, demonstrating a higher proportion of medullary bone in the cases in which the nerve was found adhered to the distal segment, and a higher proportion of cortical bone associated with the evaluations of the proximal segment.

3.6 Relations of bone density with nerve entrapment in the distal and proximal segments mandibular bone segments (Table 2)

With regard to bone density, which was measured in Hounsfield Units, after analysis of the data it was verified that for patients with presence of the nerve in the distal segment after mandibular sagittal split ramus osteotomy, the mean value at point "A" was 229 HU, 322 HU at point "B" and 389 HU at point "C". When the other possibility (nerve on the proximal segment) was analyzed, the mean measurements for points "A", "B" and "C" were: 266 HU, 364 HU and 433 HU, respectively. These results showed no statistical relevance, not even when the points were evaluated in isolation, or when they were evaluated in isolation ("ABC/3"). However, the mean bone density value was higher at all of the 3 points in patients who had the nerve bundle adhered to the proximal segment.

Table 2 - Comparison of mandibular bone characteristics and inferior alveolar nerve trajectory

Quantitative Variables	Distal			Proximal				
	Mean (IC 95%)	**S.D.**	**Mean**	**Mean (IC 95%)**	**S.D.**	**Mean**	***P***	**Dif** (IC 95%)
Thickness A	11.2 (10.5/11.8)	1.6	11.2	9.8 (8.9/10.7)	1.6	9.9	0.017*	1.4 (0.2/2.4)
Thickness B	9.8 (9.1/10.4)	1.6	9.7	8.2 (6.7/9.8)	2.6	7.7	0.027*	1.5 (0.1/2.8)
Thickness C	7.7 (7.2/8.3)	1.4	7.4	6.6 (5.9/7.3)	1.2	6.5	0.015*	1.1 (0.2/1.9)
Thickness ABC/3	9.5 (9.0/10.0)	1.2	9.4	8.2 (7.5/9)	1.3	8.1	0.002*	1.3 (0.5/2.1)
MC-BC A	2.6 (2.2/3.1)	1.0	2.7	0.7 (0.3/1.1)	0.7	0.7	<0.001	1.8 (1.2/2.5)
MC-BC B	1.4 (0.9/1.9)	1.3	1.3	0.4 (0.4/0.9)	0.8	0.0	0.016*	0.9 (0.1/1.7)
MC-BC C	0.6 (0.3/1.0)	0.8	0.4	0.5 (0.09/0.1)	0.8	0.0	0.610	0.1 (-0.4/0.6)
MC-BC ABC/3	1.6 (1.2/1.9)	0.9	1.4	0.6 (0.3/0.8)	0.4	0.4	<0.001	1.0 (0.5/1.5)
MC-LC A	0.3 (0.07/0.6)	0.8	0.0	1.4 (0.6/2.2)	1.4	0.9	0.002*	-1.0 (-1.7/-0.4)
MC-LC B	0.6 (0.1/1.0)	1.09	0.0	0.8 (-0.02/1.5)	1.4	0.0	0.646	-1.8 (-0.9/0.6)
MC-LC ABC/3	0.3 (0.1/0.5)	0.5	0.08	0.7 (0.2/1.2)	0.9	0.3	0.069	-0.4 (-0.8/0.3)
Medullary Bone A	45.2 (42.1/48.5)	7.8	44.0	43.1 (38.5/47.7)	7.9	44.0	0.404	2.2 (-3.0/7.4)
Medullary Bone B	45.1 (40.7/48.9)	10.2	42.1	39.7 (34.6/44.8)	8.7	43.3	0.124	5.0 (-1.4/11.6)
Medullary Bone C	34.6 (29.6/39.8)	12.6	34.1	30.1 (24.7/35.2)	9.0	29.6	0.229	4.6 (-3.0/12.4)
Medullary Bone ABC	41.6 (39.0/44.0)	6.6	40.3	37.6 (33.0/41.0)	7.0	40.2	0.082	3.9 (-0.5/8.5)
Cortical Bone A	54.8 (52.7/58.9)	7.6	56.3	56.1 (51.2/61.0)	8.4	54.9	0.897	-0.3 (-5.6/4.9)
Cortical Bone B	54.9 (50.8/58.9)	10.0	57.8	60.3 (55.2/65.3)	8.8	56.7	0.099	-5.3 (-11.7/1.0)
Cortical Bone C	65.4 (63.7/71.3)	9.4	66.5	69.9 (64.6/75.1)	9.1	69.7	0.447	-2.3 (-8.6/3.89)
Cortical Bone ABC3	59.4 (57.0/62.0)	6.2	60.0	63.0 (58.0/66.0)	7.0	60.0	0.221	-2.7 (-7.0/1.7)
HU A	229.0 (164.0/295.0)	162.7	248.0	266.0 (176.0/357.0)	156.0	228.0	0.495	-36.7 (-144.0/71.0)
HU B	323.0 (248.0/397.0)	184.0	338.0	364.0 (227.0/500.0)	236.0	387.0	0.546	-41.0 (-177.0/95.0)
HU C	389.0 (301.0/477.0)	218.0	366.0	433.0 (300.0/566.0)	230.0	437.0	0.554	-43.9 (-192.0/105.0)
HU ABC/3	314.0 (253.0/374.0)	151.0	310.0	354.0 (258.0/451.0)	167.0	409.0	0.440	-40 (-146.0/65.0)

IC 95%: Lower and Upper Limit for a confidence interval of 95%; SD: Standard Deviation; Mean/Measurement:() Median; Dif: Difference among the means; MC: Mandibular Canal; BC- Buccal Cortical; LC: lingual cortical; HU: Hounsfield Units

4. Discussion

In this study, computed tomography was used as the imaging exam for evaluating the anatomical characteristics of the mandibular canal, based on the affirmatives of Ylikontiola *et al.*[16] that computed tomography - whether of the helical or cone beam type - is the imaging exam of choice for these analyses. These evaluations help to minimize the most prevalent complication of mandibular sagittal split ramus osteotomy - postoperative paresthesia, which could compromise the quality of life and diminish patient satisfaction with the treatment[2, 7]. This imaging exam has shown good clinical applicability, and has enabled professionals to inform patient about the higher or lower risk of neurosensory disturbance, and to perform surgical maneuvers that diminish damage to the inferior alveolar nerve[2, 16, 17].

In this study, three points of reference in the mandibular ramus and body were selected for making a meticulous evaluation of the anatomic characteristics along the course of the mandibular canal, as was done in the some studies[16, 18, 19, 20]. However, various authors have used only one point of reference for making tomographic measurements of the mandibular canal[5, 12, 21, 22, 23, 24, 25]. This point was found in the region of the mandibular second molar, because it was the region of the vertical component of sagittal osteotomy of the mandibular ramus. The evaluation made in this study has advantages in relation to the second procedure cited, since the anatomical characteristics related to the mandibular canal were analyzed along the course of the inferior alveolar nerve. Since sagittal split osteotomy occurs along the course of the entire osteotomy, the inferior alveolar nerve is subject to damage throughout its extension and not only in the region of the mandibular second molar.

In this study the intraoperative position of the inferior alveolar nerve was grouped into two possible localizations: the proximal or distal segment. In the former there would be the need for surgical manipulation of the nerve, and in the latter, there would be the need for surgical manipulation; similar to the methodology used by Fridrich *et al.*[10]. This authors, in the same way as other researchers pointed out that one of the causes of postoperative paresthesia was manipulation of the inferior alveolar nerve after mandibular sagittal split ramus osteotomy[26, 27]. Whereas Hanzelka *et al.*[7] minimized this factor as being determining for the development of paresthesia.

In addition to manipulation of the other variables have also been described in the literature as being factors that influence paresthesia, among them we may cite: medial

retraction of the extraosseous portion of the inferior alveolar nerve, at the time of performing horizontal osteotomy of the mandibular ramus, use of chisels, material used for osteotomy, type of fixation, type of osteotomy, hematoma/edema formation in the region of the mandibular canal, time taken to perform surgery, age, sex and preoperative sensitivity[3, 7, 8, 9, 10, 17, 27, 28, 29].

In the literature, there is a scarcity of data related to analysis of the anatomical characteristics of mandibular canal and intraoperative position of the inferior alveolar nerve after mandibular sagittal split osteotomy. Many authors have correlated the mandibular canal anatomy with postoperative paresthesia, by means of computed tomography, and have concluded that reduction in the distance from the inferior alveolar nerve to the buccal cortical bone, and reduction in the mandibular (bone) thickness increased the risk for development of paresthesia of the inferior alveolar nerve after mandibular sagittal split ramus osteotomy[5, 16, 18, 20, 23, 25, 30, 31]. However, these studies did not include the intraoperative position of the inferior alveolar nerve after mandibular sagittal split ramus osteotomy as a variable analyzed. This is why a greater degree of manipulation of the nerve is understood to lead to a greater chance of the occurrence of postoperative paresthesia[27].

In the present study, in patients of the female gender, 41% of the nerves were adhered to the proximal segment after sagittal split ramus osteotomy, while in the male sex only 27.8% of the nerves were adhered to the proximal segment. This could be explained by the fact that the distance from the mandibular canal to the buccal cortical bone was significantly shorter ($p<0.05$) in the female sex, in this study than that of the male sex, corroborating the literature [5, 12, 32]. This favored the presence of the nerve in the proximal segment after sagittal split ramus osteotomy, and demonstrated the greater possibility of manipulating and damaging the nerve. These data and the affirmation made by others[10, 26, 27] that surgical manipulation of the inferior alveolar nerve promoted a higher incidence of neurosensory disturbance, thus justifying the finding of some authors who affirmed that patients of the female gender had a greater tendency to develop paresthesia than patients of the male gender[5, 28]. To the contrary, some authors[7] found no relationship between paresthesia and gender.

The most important findings of this study were that the mandibular (bone) thickness and distances from the mandibular canal to the buccal and lingual cortical bones were significantly correlated with the intraoperative position of the inferior alveolar nerve.

The distance from the mandibular canal to the internal service of the buccal cortical bone showed significantly lower mean values in the group in which the nerve was adhered to the proximal segment in the regions of the second and third molars in the present study. This analysis could not be compared because, in the literature there are no researches that provide this information. However, researchers have affirmed that the reduction in the distance from the mandibular canal to the buccal cortical bone promoted higher risk for neurosensory disturbance both in the short and long term [5, 16, 18, 20, 23, 24, 25, 30, 31]. This could be explained by the datum presented above, which consists of the higher incidence of inferior alveolar nerves adhered to the proximal segment when these distances are diminished, therefore requiring surgical manipulation of the inferior alveolar nerve. Therefore, knowing about the affirmations made by some authors [10, 26, 27], that more extensive surgical manipulation leads to greater chance of neurosensory disturbance, these data served as justification for the finding of the relationship between the distance from the mandibular canal to the buccal cortical bone and postoperative paresthesia. Furthermore, Yoshioka *et al.*[23] affirmed that when the distance from the mandibular canal to the buccal cortical bone was diminished, the inferior alveolar nerve was more subject to suffering injury during surgical procedures such as mandibular sagittal split ramus osteotomy.

Some authors provided objective measurements of risk related to the distance from the mandibular canal to the buccal cortical bone for the development of postoperative paresthesia, Ylikontiola *et al.*[16] reported that the risk for neurosensory disturbance increased significantly when this distance was equal to or shorter than 2 mm. Yoshida *et al.*[30] in their study, affirmed that distances shorter than 1.2 mm were found in 91% of the sides with severe neurosensory disturbance, and Yamamoto *et al.*[18] found that distances shorter than 0.8 mm increased the risk of permanence of paresthesia 1 year after the surgical procedure. Yoshioka *et al.*[23] affirmed that distances shorter than 6 mm increased the chance of neurological damage occurring. The latter author performed these measurements using the external cortical and not the internal surface of the external cortical as reference, and therefore showed higher values than the other authors. In this study, 92.8% of the nerves that remained adhered to the proximal segment had distances from the mandibular canal to the buccal cortical bone shorter than 2 mm and 78.5% showed distances shorter than or equal to 1 mm. The justification for the relations among these data (anatomy, intraoperative position and paresthesia) is the same as that presented in the paragraph above.

The course of the inferior alveolar nerve has been demonstrated to be extremely close to the buccal cortical, without spongy bone between the mandibular canal and the buccal cortical bone during the course of its trajectory up to the region of the mandibular second molar. Tamas *et al.*[33] found an incidence of 19.5% of these cases in their studies conducted by means X-rays of dry mandibles. In the present study an incidence of 10% was found of the distance of mandibular canals to the buccal cortical bone in all the regions evaluated, and in all of these cases the nerve remained adhered to the proximal segment after split sagittal osteotomy. Tsuji *et al.*[1], after analyses of computed tomography images, affirmed that 22.9% of the cases evaluated showed some area of fusion of the mandibular canal to the buccal cortical bone in the region from the mandibular foramen to the region of the mandibular body, however, no case of fusion was shown in all the (other) regions evaluated. Yamamoto *et al.*[18], reported the presence of fusion in 25% of the cases, however, fusion was found only in the region of the mandibular body.

Another important finding in this study was that the distance from the mandibular canal to the internal surface of the lingual cortical bone showed significantly higher mean values ($p<0,05$) at point "A" in the patients in whom the nerve was adhered to the proximal segment, after split sagittal ramus osteotomy, in the region of the mandibular second molar. Ylikontiola *et al.*[16] verified that the mean distance from the mandibular canal to the lingual cortical bone was 2.25 mm, ranging from 1 to 5 mm in the region of the mandibular third molar and a mean of 2.25 mm ranging between 0.8 and 5 mm in the region between the maxillary first and second molars. However, they did not relate this datum to paresthesia or the segment to which the nerve remained adhered in the surgical procedure. In the present study, the mean value obtained in the region of the mandibular third molar was 0.6 mm ranging from 0 to 4.4 mm and a mean of 0.7 mm ranging between 0 and 4.2 mm in the region of the mandibular second molar. Simonton *et al.*[32] also evaluated this variable, however, with the aim of finding differences between the male and female genders, and found no significant difference in this analysis. The mean value found by this author was 2.4 mm in the region of the mandibular first molar. The mean values in the study of Simonton[32] and Ylikontiola *et al.*[16] were higher than those found in the present study, because they made their measurements from the mandibular canal to the external surface of the lingual cortical bone of the mandible. The distance from the mandibular canal to the external cortical at point

"C" was 0 mm in all the patients, confirming the findings of Gowgiel[34], representing fusion of the mandibular canal with the lingual cortical bone in the mentioned region.

Another factor that had a significant influence on the intraoperative position of the inferior alveolar nerve after split sagittal osteotomy in this study, was the mandibular (bone) thickness. Therefore, the smaller the mandibular (bone) thickness was, the greater was the chance of the inferior alveolar nerve remaining adhered to the proximal segment. This analysis showed statistical significance in the 3 regions evaluate in isolation (point "A", "B" and "C") as well as in the 3 regions evaluated in conjunction ("ABC/3"). According to Ylikontiola *et al.*[16], the chance of neurological damage increases when the surgery is performed in narrow mandibles, and in these cases, shorter distances are generally observed between the mandibular canal and the buccal cortical of the mandible; this finding was also observed by Tamas[33]. When making an association with the present study, we could relate these affirmatives to the higher presence of the nerve on the proximal segment in narrow mandibles, leading to greater need for manipulation of the inferior alveolar nerve, and a smaller quantity of spongy bone surrounding and protecting the inferior alveolar nerve in split sagittal osteotomy procedures. These were some of the factors that favored greater neurological damage.

The proportion of cortical/medullary bone was slightly higher when the nerve was found adhered to the proximal segment in the 3 points evaluated, with greater differences being observed in the region of the mandibular third molar, however, this difference was not statistically significant. There are no studies that have compared the proportion of cortical/medullary bone with the nerve bundle after sagittal split ramus osteotomy, or with postoperative paresthesia.

The quantity of bone in the region of the inferior alveolar nerve was evaluated by Yoshioka *et al.*[22] who found that the higher the bone density value, measured in Hounsfield Units, the greater the chance of paresthesia occurring in the postoperative period. One year later, the same author published objective bone density measurements, and affirmed that patients with bone density values higher than 300 Hounsfield unit had greater chance of developing paresthesia in the long term. In the present study bone density was related to the position of the inferior alveolar nerve after sagittal split osteotomy postoperatively, and no statistically significant measurements, were found, however, when the nerve remained adhered to the proximal segment, the mean bone density values were observed to be higher,

when compared with the other outcome, in all of the 3 points evaluated. A possible explanation for this facto could be that when the bone is denser, fracture occurs in a less predictable manner since more force would be applied to perform the mandibular sagittal spit ramus osteotomy[23]. Furthermore, Yoshioka *et al.* [23] affirmed that in these cases greater impact of the fracture leads to higher temperatures in the bone, resulting in greater neurological damage.

When faced with these findings, the surgeon could prepare better planning and perform the surgical procedure more predictably and cautiously in cases in which the tomography image reveals risk factors for neurosensory disturbance[2, 12, 16, 18, 19, 36]. This study demonstrated that computed tomography could be useful in planning and predicting a greater or lesser extent of manipulation of the inferior alveolar nerve, making it possible to perform individualized osteotomies in cases of mandibular canal proximity to the buccal cortical bone. The osteotomies performed in the patients of the present study were not changed; they were performed with reciprocating saws and by positioning the sagittal osteotomy at a point that was half of the buccolingual distance from the mandible.

Based on this affirmation, Wittwer *et al.* [19] analyzed the position of the mandibular canal in 3 regions of the mandible and proposed modifications in the sagittal osteotomy, based on the preoperative anatomy. Of the 102 rami evaluated, only 39% were indicated for undergoing conventional osteotomies and the remainder, as they had a relationship of proximity to the inferior alveolar nerve, were included in the group with modified osteotomies, based on virtual surgical planning. The first variation was denominated modified classical osteotomy, and was indicated for cases in which there was a relationship of proximity between the mandibular canal and the buccal cortical bone in the region of the mandibular third molar, and/or in the region of transition from the ramus to the mandibular body. This variation consisted of osteotomy aided by navigation, in the buccal region of the mandible, and traditional, in the region of the mandibular ramus, with a view to avoiding nerve damage in the region of transition from the ramus to the mandibular body. The second variation was denominated completely individualized osteotomy, and was developed for cases that the area of the mandibular canal is close to the buccal cortex in the region before reaching the mandibular foramen. This type of osteotomy requires the use of surgery by navigation throughout its entire extension, and in this case, the buccal part of the osteotomy is not performed. A disadvantage of this study was that there was no clinical application of

the modified osteotomies, and its use was only tested in software programs, so that there was no clinical and scientific evidence to support it.

Yu and Wong[12] suggested a guideline for surgeons to avoid neurological damage when medial osteotomy has to be performed 5 mm in the superior direction and 4 to 8 mm in the posterior direction to the lingual bone cortex. Sagittal osteotomy must not penetrate the medullary bone by more than 8 mm, and at the buccal bone cortical the osteotomy must not exceed 5 mm in the direction of the mandibular medullary bone. In spite of this, Yu and Wong[12] supported the practice of performing individualized osteotomies in selected cases. This concern about the modifications made to osteotomy has been demonstrated by some authors, such as Yoshida *et al.*[30], who reported performing vertical osteotomy in a more posterior position than in the conventional procedure, as being a factor that diminished nerve damage. Furthermore, they reported the use of a thin cement spatula to perform the mandibular sagittal split ramus osteotomy in cases in which they observed small distances between the mandibular canal and buccal cortical bone. This suggestion was also made by Brusati *et al.*[36], who performed this technique in 20 patients. Of the 40 sides evaluated, only 1 had paresthesia in the long term. This type of approach would avoid direct damage to the inferior alveolar nerve and would allow the presence of a larger quantity of medullary bone covering the mandibular canal. In a systematic review, Mensink et al.[16] suggested that the use of a hammer and chisel to perform split sagittal osteotomy showed greater chances of damaging the inferior alveolar nerve when compared with the use of separators, as described by Wolford *et al.*[36].

Aizenbud *et al.*[2], in their studies, performed mandibular sagittal split ramus osteotomies in patients with and without undergoing preoperative computed tomography exams. The osteotomies were performed according to the preoperative anatomy in the first case, and conventional osteotomies in the second case. The authors believed that the low incidence of postoperative paresthesia in the first group (approximately 75% fewer cases than in the second group) were due to the modifications made to the osteotomies, namely: in thick mandibular bone, it was not necessary to perform the osteotomy in the middle of the mandible (buccolingual direction) but rather according to the position of the nerve; the vertical component of the sagittal osteotomy could be modified according to the mandibular canal anatomy, thereby minimizing intraoperative manipulation of the inferior alveolar nerve and postoperative paresthesia.

Two limitations of this study were the small sample and the fact that only the anatomy of the mandibular canal and intraoperative position of the inferior alveolar nerve were evaluated. Whereas postoperative paresthesia was not evaluated, so that there were no conclusion involving paresthesia based on this study. In view of the foregoing, future studies are being planned.

5. Conclusions

1. Reduction in the distance from the mandibular canal to the internal surface of the buccal cortical bone in the regions of the mandibular second and third molars increased the chance of inferior alveolar nerve being adhered to the proximal segment after mandibular sagittal split ramus osteotomy;
2. Increase in the distance from the mandibular canal to the internal surface of the lingual cortical bone in the regions of the mandibular second molar increased the chance of inferior alveolar nerve being adhered to the proximal segment after mandibular sagittal split ramus osteotomy;
3. The chance of the inferior alveolar nerve being adhered to the proximal segment after mandibular sagittal split ramus osteotomy was increased in narrow mandibles.
4. The proportion of cortical and medullary bone and bone density did not significantly contribute to the outcome of this study;
5. In this study, patients of the female gender showed lower mean values of the distance from the mandibular canal to the buccal cortical bone when compared with patients of the male sex.

III. NORMAS PARA PREPARAÇÃO DO ARTIGO CIENTÍFICO

III. NORMAS PARA PREPARAÇÃO DE ARTIGO CIENTIFICO

GUIDE FOR AUTHORS

Section Scope Statements

The *Oral and Maxillofacial Surgery Section* aims to publish an extensive range of original articles that advances patient care through enhanced understanding of diagnosis, surgical and adjunctive treatment of diseases, and injuries and defects involving both the functional and esthetic aspects of the hard and soft tissues of the oral and maxillofacial regions. The section also seeks research regarding both the basic science of and management of persons with oral and maxillofacial conditions. Articles presenting ethical, original, well-documented, and reproducible research are given preference.

The *Oral Medicine Section* aims to publish a broad range of original articles that help clinicians understand more thoroughly the pathobiology, etiology, diagnosis, prevention, and management of oral conditions related to underlying medical conditions, including diseases of the head, neck, and oral mucosal structures, orofacial pain conditions, salivary gland disorders, and taste disorders. The section also seeks research regarding the dental management of persons with medical problems and/or complicated medical conditions. The published findings must contribute substantively to the body of oral medicine literature and should lead to improved clinical decision-making and enhanced care of medically-related disorders or conditions affecting the oral and maxillofacial region. Articles presenting original, well-documented, and reproducible research are preferred.

The *Oral and Maxillofacial Pathology Section* encourages the submission of original articles of high scientific quality that investigate the pathogenesis, diagnosis, and management of diseases affecting the oral and maxillofacial region. Submitted manuscripts may summarize findings from clinical, translational, or basic research in the broad field of oral and maxillofacial pathology but must contribute substantively to the body of knowledge in this field and should be of obvious clinical and/ or diagnostic significance to the practicing oral and maxillofacial pathologist. Areas of focus may include the investigation of disease pathogenesis, the diagnosis of disease using microscopic, clinical, radiographic, biochemical, molecular, or other methods as well as the natural history and management of patients with various conditions of the head, neck, and oral mucosal structures. Diagnostic accuracy studies should conform to the principles of the STARD document http://www.stard-statement.org. Articles presenting novel and reproducible research that introduce new knowledge and observations are especially encouraged. This section also welcomes the submission of topical review papers on relevant subjects.

The *Oral and Maxillofacial Radiology Section* publishes original contributions to the advancement of oral and maxillofacial radiology and related imaging sciences. The section considers original clinical and experimental research papers, reports of technological developments, extensive systematic reviews of the literature, and invited papers on subjects that will appeal to researchers and clinicians involved in diagnostic imaging of hard and soft tissues of the head and neck. Topics of interest include the efficacy of imaging systems using ionizing and non-ionizing radiation in the diagnosis of head and neck disease; molecular imaging; artificial intelligence and computer-assisted diagnosis; craniofacial analysis; image-guided surgical navigation; image processing; radiation physics and dosimetry; and radiation biology, safety, and protection. The section also seeks extensive case series representing various expressions of particular conditions, descriptions of innovative imaging technique applications to these series, and description of novel imaging features. Published manuscripts should assist clinicians in developing evidence-based practice and provide improved clinical decision-making regarding the performance of specific techniques and interpretation of resulting images. Diagnostic accuracy studies should conform to the principles of the STARD document http://www.stard-statement.org).

Types of Papers

1. Original Research Article. Reports of original research (preclinical, clinical, or translational) that are well-documented, novel, and significant. Original research manuscripts will be organized into six parts: (1) Abstract; (2) Introduction; (3) Materials and Methods; (4) Results; (5) Discussion; (6) References.

2. Review article. Manuscripts that review the current status of a given topic, diagnosis, or treatment. These manuscripts should not be an exhaustive review of the literature but rather should be a review of contemporary thought with respect to the topic. Systematic reviews and meta-analyses manuscripts should follow PRISMA (http://www.prisma-statement.org) and the Institute of Medicines' guidelines (http://www.iom.edu/Reports/2011/Finding-What-Works-in-Health-Care-Standards-for-Systematic-Reviews,

3. Clinicopathologic Conference (CPC). Manuscripts that document interesting, challenging, or unusual cases that present unexpected or interesting diagnostic challenges. The presentation should simulate clinical work-up, including the formulation of a detailed and well thought out differential diagnosis. The complete diagnostic evaluation, management, and follow-up must be included. CPC articles must be organized into six parts: (1) Title: Provide a descriptive clinical title that does not reveal the final diagnosis. (2) Clinical presentation: Describe the clinical and imaging characteristics of the lesion. Use clinical photographs and radiographs as appropriate. (3) Differential diagnosis: List and discuss lesions to be considered as reasonable diagnostic possibilities. The authors are reminded that the most important part of the CPC manuscript is the clinical differential diagnosis, where the authors guide the readership through their own diagnostic thought process. This will require the formulation of a list of the most probable diagnostic possibilities (ideally at least 5-6 entities) based on the clinical presentation, medical history, and/or radiographic studies. (4) Diagnosis: Histopathologic findings illustrated with appropriate photomicrographs. (5) Management: Describe the treatment of the patient and response to treatment. (6) Discussion: Concentrate on the most interesting aspect(s) of the case. No abstract is needed for CPC manuscripts. Limit the number of references to no more than 25.

4. Case Reports. These types of publications often add little to the scientific knowledge base. However, excellent case reports may be published as online only papers if they meet certain criteria, such as: (1) rare or unusual lesions/conditions that need documentation, (2) well-documented cases showing unusual or "atypical" clinical or microscopic features or behavior, or (3) cases showing good long-term follow-up information, particularly in areas in which good statistics on results of treatment are needed. A case report should either present unique features of the condition or lesion, novel treatment regimens, or provide the basis for a new plausible medical theory about the pathogenesis of a particular disease or condition so clinicians can provide better care regarding patients with chronic and painful conditions relevant to medical disorders and/or medical therapy. Providing Virtual Microscope image/s is highly encouraged for Case Reports (see also below).

Enhancements such as Virtual Microscope images, DICOM files, and video clips are not mandatory for initial submission but are encouraged for all article types; if editors request a revision, they may specifically request submission of these types of files with the revised manuscript.

General inquiries and communications regarding editorial management should be addressed to Alice M. Landwehr, Managing Editor: tripleOjournal@gmail.com.
General correspondence to the Editor-in-Chief, Mark W. Lingen, DDS, PhD: Mark.Lingen@uchospitals.edu
Publisher-specific inquiries should be addressed to: Jane Ryley, Elsevier Inc., 3251 Riverport Lane, Maryland Heights, MO 63043; e-mail: J.Ryley@Elsevier.com.
Issue Manager, Elizabeth Rajesh; e-mail: e.rajesh@Elsevier.com.

BEFORE YOU BEGIN

Ethics in publishing

Please see our information pages on Ethics in publishing and Ethical guidelines for journal publication.

Declaration of interest

All authors must disclose any financial and personal relationships with other people or organizations that could inappropriately influence (bias) their work. Examples of potential competing interests include employment, consultancies, stock ownership, honoraria, paid expert testimony, patent applications/registrations, and grants or other funding. Authors must disclose any interests in two places: 1. A summary declaration of interest statement in the title page file (if double-blind) or the manuscript file (if single-blind). If there are no interests to declare then please state this: 'Declarations of interest: none'. This summary statement will be ultimately published if the article is accepted. 2. Detailed disclosures as part of a separate Declaration of Interest form, which forms part of the journal's official records. It is important for potential interests to be declared in both places and that the information matches. More information.

If there is any overlap between the submission and any other material, published or submitted, detail the nature of and reason for the overlap for the editors' assessment. Although poster presentations and abstracts are not considered duplicate publication, they should be stated on the title page. Further information about Elsevier's standards for publication ethics is available at https://www.elsevier.com/publishingethics.

Submission declaration and verification

Submission of an article implies that the work described has not been published previously (except in the form of an abstract, a published lecture or academic thesis, see 'Multiple, redundant or concurrent publication' for more information), that it is not under consideration for publication elsewhere, that its publication is approved by all authors and tacitly or explicitly by the responsible authorities where the work was carried out, and that, if accepted, it will not be published elsewhere in the same form, in English or in any other language, including electronically without the written consent of the copyright-holder. To verify originality, your article may be checked by the originality detection service Crossref Similarity Check.

Preprints

Please note that preprints can be shared anywhere at any time, in line with Elsevier's sharing policy. Sharing your preprints e.g. on a preprint server will not count as prior publication (see 'Multiple, redundant or concurrent publication' for more information).

Use of inclusive language

Inclusive language acknowledges diversity, conveys respect to all people, is sensitive to differences, and promotes equal opportunities. Articles should make no assumptions about the beliefs or commitments of any reader, should contain nothing which might imply that one individual is superior to another on the grounds of race, sex, culture or any other characteristic, and should use inclusive language throughout. Authors should ensure that writing is free from bias, for instance by using 'he or she', 'his/her' instead of 'he' or 'his', and by making use of job titles that are free of stereotyping (e.g. 'chairperson' instead of 'chairman' and 'flight attendant' instead of 'stewardess').

Author contributions

For transparency, we encourage authors to submit an author statement file outlining their individual contributions to the paper using the relevant CRediT roles: Conceptualization; Data curation; Formal analysis; Funding acquisition; Investigation; Methodology; Project administration; Resources; Software; Supervision; Validation; Visualization; Roles/Writing - original draft; Writing - review & editing. Authorship statements should be formatted with the names of authors first and CRediT role(s) following. More details and an example

Authorship

All authors should have made substantial contributions to all of the following: Substantial contributions to the conception or design of the work; or the acquisition, analysis, or interpretation of data for the work; AND Drafting the work or revising it critically for important intellectual content; AND Final approval of the version to be published; AND Agreement to be accountable for all aspects of the work in ensuring that questions related to the accuracy or integrity of any part of the work are appropriately investigated and resolved. All authors must have seen and approved the submission of the manuscript and be willing to take responsibility for the entire manuscript. All persons listed as authors must meet the criteria for authorship according to the "Uniform Requirements for Manuscripts Submitted to Biomedical Journals: Writing and Editing for Biomedical Publication" available at http://www.icmje.org. All four of these conditions must be met by each author. No additional authors can be added after submission unless editors receive agreement from all authors and detailed information is supplied as to why the author list should be amended. Persons who contribute to the effort in supporting roles should not be included as authors; they should be acknowledged at the end of the paper (see Acknowledgments below).

Changes to authorship

Authors are expected to consider carefully the list and order of authors **before** submitting their manuscript and provide the definitive list of authors at the time of the original submission. Any addition, deletion or rearrangement of author names in the authorship list should be made only **before** the manuscript has been accepted and only if approved by the journal Editor. To request such a change, the Editor must receive the following from the **corresponding author**: (a) the reason for the change in author list and (b) written confirmation (e-mail, letter) from all authors that they agree with the addition, removal or rearrangement. In the case of addition or removal of authors, this includes confirmation from the author being added or removed.

Only in exceptional circumstances will the Editor consider the addition, deletion or rearrangement of authors **after** the manuscript has been accepted. While the Editor considers the request, publication of the manuscript will be suspended. If the manuscript has already been published in an online issue, any requests approved by the Editor will result in a corrigendum.

Registration of clinical trials
Registration in a public trials registry is a condition for publication of clinical trials in this journal in accordance with International Committee of Medical Journal Editors recommendations. Trials must register at or before the onset of patient enrolment. The clinical trial registration number should be included at the end of the abstract of the article. A clinical trial is defined as any research study that prospectively assigns human participants or groups of humans to one or more health-related interventions to evaluate the effects of health outcomes. Health-related interventions include any intervention used to modify a biomedical or health-related outcome (for example drugs, surgical procedures, devices, behavioural treatments, dietary interventions, and process-of-care changes). Health outcomes include any biomedical or health-related measures obtained in patients or participants, including pharmacokinetic measures and adverse events. Purely observational studies (those in which the assignment of the medical intervention is not at the discretion of the investigator) will not require registration.

Clinical trial results
In line with the position of the International Committee of Medical Journal Editors, the journal will not consider results posted in the same clinical trials registry in which primary registration resides to be prior publication if the results posted are presented in the form of a brief structured (less than 500 words) abstract or table. However, divulging results in other circumstances (e.g., investors' meetings) is discouraged and may jeopardise consideration of the manuscript. Authors should fully disclose all posting in registries of results of the same or closely related work.

Article transfer service
This journal is part of our Article Transfer Service. This means that if the Editor feels your article is more suitable in one of our other participating journals, then you may be asked to consider transferring the article to one of those. If you agree, your article will be transferred automatically on your behalf with no need to reformat. Please note that your article will be reviewed again by the new journal. More information.

Copyright
Upon acceptance of an article, authors will be asked to complete a 'Journal Publishing Agreement' (see more information on this). An e-mail will be sent to the corresponding author confirming receipt of the manuscript together with a 'Journal Publishing Agreement' form or a link to the online version of this agreement.

Subscribers may reproduce tables of contents or prepare lists of articles including abstracts for internal circulation within their institutions. Permission of the Publisher is required for resale or distribution outside the institution and for all other derivative works, including compilations and translations. If excerpts from other copyrighted works are included, the author(s) must obtain written permission from the copyright owners and credit the source(s) in the article. Elsevier has preprinted forms for use by authors in these cases.

For gold open access articles: Upon acceptance of an article, authors will be asked to complete an 'Exclusive License Agreement' (more information). Permitted third party reuse of gold open access articles is determined by the author's choice of user license.

Author rights
As an author you (or your employer or institution) have certain rights to reuse your work. More information.

Elsevier supports responsible sharing
Find out how you can share your research published in Elsevier journals.

Role of the funding source

You are requested to identify who provided financial support for the conduct of the research and/or preparation of the article and to briefly describe the role of the sponsor(s), if any, in study design; in the collection, analysis and interpretation of data; in the writing of the report; and in the decision to submit the article for publication. If the funding source(s) had no such involvement then this should be stated.

Open access

Please visit our Open Access page for more information.

Language (usage and editing services)

Please write your text in standard, grammatical English (American or British usage is accepted, but not a mixture of these). Authors who feel their English language manuscript may require editing to eliminate possible grammatical or spelling errors and to conform to correct scientific English may wish to use the English Language Editing service available from Elsevier's WebShop (http://webshop.elsevier.com/languageediting/) or visit our customer support site (https://service.elsevier.com) for more information. Such assistance does not guarantee acceptance but may enhance the review, improve the chance of acceptance, and reduce the time until publication if the article is accepted.

Informed consent and patient details

Studies on patients or volunteers require ethics committee approval and informed consent, which should be documented in the paper. Appropriate consents, permissions and releases must be obtained where an author wishes to include case details or other personal information or images of patients and any other individuals in an Elsevier publication. Written consents must be retained by the author but copies should not be provided to the journal. Only if specifically requested by the journal in exceptional circumstances (for example if a legal issue arises) the author must provide copies of the consents or evidence that such consents have been obtained. For more information, please review the Elsevier Policy on the Use of Images or Personal Information of Patients or other Individuals. Unless you have written permission from the patient (or, where applicable, the next of kin), the personal details of any patient included in any part of the article and in any supplementary materials (including all illustrations and videos) must be removed before submission.

Submission

Our online submission system guides you stepwise through the process of entering your article details and uploading your files. The system converts your article files to a single PDF file used in the peer-review process. Editable files (e.g., Word, LaTeX) are required to typeset your article for final publication. All correspondence, including notification of the Editor's decision and requests for revision, is sent by e-mail.If the manuscript is accepted, the Editors reserve the right to determine whether it will be published in the print edition or solely in the Internet edition of the Journal.

Submit your article

Please submit your article via https://www.editorialmanager.com/tripleO/default.aspx.

PREPARATION

Use of word processing software

It is important that the file be saved in the native format of the word processor used. The text should be in single-column format. Keep the layout of the text as simple as possible. Most formatting codes will be removed and replaced on processing the article. In particular, do not use the word processor's options to justify text or to hyphenate words. However, do use bold face, italics, subscripts, superscripts etc. When preparing tables, if you are using a table grid, use only one grid for each individual table and not a grid for each row. If no grid is used, use tabs, not spaces, to align columns. The electronic text should be prepared in a way very similar to that of conventional manuscripts (see also the Guide to Publishing with Elsevier). Note that source files of figures, tables and text graphics will be required whether or not you embed your figures in the text. See also the section on Electronic artwork.

To avoid unnecessary errors you are strongly advised to use the 'spell-check' and 'grammar-check' functions of your word processor.

LaTeX

You are recommended to use the Elsevier article class elsarticle.cls to prepare your manuscript and BibTeX to generate your bibliography.

Our LaTeX site has detailed submission instructions, templates and other information.

Article structure

Essential Title Page Information

The title page of the manuscript should include the title of the article, the full name of the author(s), academic degrees, positions, and institutional affiliations. The corresponding author's address, business and home telephone numbers, fax number, and e-mail address should be given. Disclosures must appear on the title page (see *Disclosures*).

• ***Title.*** Concise and informative. Titles are often used in information-retrieval systems. Avoid abbreviations and formulae where possible.
• ***Author names, academic degrees, positions, and institutional affiliations.*** Where the family name may be ambiguous (e.g., a double name), please indicate this clearly. Present the authors' affiliation addresses (where the actual work was done) below the names. Indicate all affiliations with a lower-case superscript letter immediately after the author's name and in front of the appropriate address. Provide the full postal address of each affiliation, including the country name and, if available, the e-mail address of each author.
• ***Corresponding author.*** Clearly indicate who will handle correspondence at all stages of refereeing and publication, also post-publication. **Ensure that phone numbers (with country and area code) are provided in addition to the e-mail address and the complete postal address. Contact details must be kept up to date by the corresponding author.**
• ***Present/permanent address.*** If an author has moved since the work described in the article was done, or was visiting at the time, a 'Present address' (or 'Permanent address') may be indicated as a footnote to that author's name. The address at which the author actually did the work must be retained as the main, affiliation address. Superscript Arabic numerals are used for such footnotes.
• **Disclosures** must appear on the title page (see "Conflict of Interest" above).

Include on the title page a word count for the abstract (if relevant to article type), a complete manuscript word count (to include body text and figure legends), number of references, number of figures/tables, and number of supplementary elements, if any (eg, Virtual Microscope image/s, video clip files, DICOM files, extensive tables, figures, description of methodology).

Include on the title page any disclosures including funding, disclaimer statements, presentation/s of the research at conferences/symposia, posting of the work on a preprint server, website, or other location.

Highlights

Highlights are optional yet highly encouraged for this journal, as they increase the discoverability of your article via search engines. They consist of a short collection of bullet points that capture the novel results of your research as well as new methods that were used during the study (if any). Please have a look at the examples here: example Highlights.

Highlights should be submitted in a separate editable file in the online submission system. Please use 'Highlights' in the file name and include 3 to 5 bullet points (maximum 85 characters, including spaces, per bullet point).

Statement of Clinical Relevance

For Original research and Review manuscripts, please provide a brief statement of no more than 40 words that succinctly summarizes the clinical relevance of the findings described in your manuscript. For example:

"The risk of postoperative bleeding complications in patients in whom anticoagulation is continued for dental surgery is exceedingly small and is outweighed by the small risk of serious and sometimes fatal embolic events when anticoagulation is interrupted for dental surgery." (Wahl et al. 119(2) https://doi.org/10.1016/j.oooo.2014.10.011)

Abstract

A structured abstract, limited to 200 words, must be used for data-based research articles. The structured abstract is to contain the following major headings: Objective(s); Study Design; Results; and Conclusion(s). The Objective(s) reflects the purpose of the study, that is, the hypothesis that is being tested. The Study Design should include the setting for the study, the subjects (number and type), the treatment or intervention, and the type of statistical analysis. The Results include

the outcome of the study and statistical significance if appropriate. The Conclusion(s) states the significance of the results. For nondata-based submissions, the abstract should be an unstructured summary of less than 150 words. No abstract is needed for submissions to the CPC section.

Subdivision - unnumbered sections

Divide your article into the following clearly defined sections. Each subsection is given a brief heading. Each heading should appear on its own separate line. Subsections should be used as much as possible when cross-referencing text: refer to the subsection by heading as opposed to simply 'the text'.

Introduction

State the problem being investigated, summarize the existing knowledge to place the problem in context, and describe the hypothesis and general experimental design. Avoid a detailed literature survey or a summary of the results.

Materials and Methods

As relevant, the Materials and Methods section should describe in adequate detail the experimental subjects, their important characteristics, and the methods, apparatus, and procedures used so that other researchers can reproduce the experiment. When the manuscript submitted reports on research in which humans are involved as experimental subjects directly or indirectly, the Materials and Methods section must indicate that the protocol was reviewed by the appropriate institutional review board (IRB), is in compliance with the Helsinki Declaration, and that each subject in the project signed a detailed informed consent form. Authors should verify compliance with the Health Insurance Portability and Accountability Act of 1996 (HIPAA) before submission. Provide sufficient detail to allow the work to be reproduced. Methods already published should be indicated by a reference; only relevant modifications should be described.

Animals. Please indicate that protocols were reviewed by the appropriate institutional committee with respect to the humane care and treatment of animals used in the study.

Results

Results should be clear and concise and presented in a logical sequence. Tables and illustrations may be helpful in clarifying the findings and can reduce the length of the manuscript.

Discussion

The Discussion states the significance of the results and limitations of the study. Authors should discuss their findings in the framework of previously published research. They should explain why their results support or contradict existing knowledge. If appropriate, the authors may suggest further research to follow up on their findings.

Formatting of funding sources
List funding sources in this standard way to facilitate compliance to funder's requirements:

Funding: This work was supported by the National Institutes of Health [grant numbers xxxx, yyyy]; the Bill & Melinda Gates Foundation, Seattle, WA [grant number zzzz]; and the United States Institutes of Peace [grant number aaaa].

It is not necessary to include detailed descriptions on the program or type of grants and awards. When funding is from a block grant or other resources available to a university, college, or other research institution, submit the name of the institute or organization that provided the funding.

If no funding has been provided for the research, please include the following sentence:

This research did not receive any specific grant from funding agencies in the public, commercial, or not-for-profit sectors.

Units
Follow internationally accepted rules and conventions: use the international system of units (SI). If other units are mentioned, please give their equivalent in SI.

Dental Nomenclature. Because of competing dental nomenclature systems, confusion can be eliminated by identifying teeth by their name, rather than a number or letter. Be consistent throughout the manuscript.

In tables, use the Universal Numbering System to identify the teeth. For example, the maxillary right permanent lateral incisor is designated tooth 7. The mandibular right deciduous second molar is designated tooth T. Identify the numbers/letters in the footnote to the table like any other abbreviations.

Math formulae

Present simple formulae in the line of normal text where possible and use the solidus (/) instead of a horizontal line for small fractional terms, e.g., X/Y. In principle, variables are to be presented in italics. Powers of e are often more conveniently denoted by exp. Number consecutively any equations that have to be displayed separately from the text (if referred to explicitly in the text).

Footnotes

Footnotes should be used sparingly. Number them consecutively throughout the article. Many word processors can build footnotes into the text, and this feature may be used. Otherwise, please indicate the position of footnotes in the text and list the footnotes themselves separately at the end of the article. Do not include footnotes in the Reference list.

Acknowledgments

The names of persons who have contributed substantially to a manuscript but who do not fulfill the criteria for authorship, along with their conflicts of interest, funding sources, and industry relations, if relevant, are to be listed in the Acknowledgment section. This section should include individuals who provided any writing, editorial, statistical assistance, etc. Collate acknowledgments in a separate section at the end of the article before the references and do not, therefore, include them on the title page, as a footnote to the title or otherwise. Do not include statements of the authors' funding, conflicts, or other disclosures in the Acknowledgments; these must appear on the title page.

References

Citation in text

References should be complete and reflect the current state of knowledge on the topic. Make sure all references have been verified and are cited consecutively in the text (not including tables) by superscript numbers. The reference list should be typed double-spaced on a separate page of the manuscript file and numbered in the same order as the reference citations appear in the text.

Please ensure that every reference cited in the text is also present in the reference list (and vice versa). Any references cited in the abstract must be given in full. Unpublished results and personal communications are not to be cited in the reference list but are to be cited in parentheses at the appropriate place in the text. Citation of a reference as 'in press' implies that the item has been accepted for publication, and publication information must be updated if the manuscript is accepted.

Reference links

Increased discoverability of research and high quality peer review are ensured by online links to the sources cited. In order to allow us to create links to abstracting and indexing services, such as Scopus, CrossRef and PubMed, please ensure that data provided in the references are correct. Please note that incorrect surnames, journal/book titles, publication year and pagination may prevent link creation. When copying references, please be careful as they may already contain errors. Use of the DOI is highly encouraged.

A DOI is guaranteed never to change, so you can use it as a permanent link to any electronic article. An example of a citation using DOI for an article not yet in an issue is: VanDecar J.C., Russo R.M., James D.E., Ambeh W.B., Franke M. (2003). Aseismic continuation of the Lesser Antilles slab beneath northeastern Venezuela. Journal of Geophysical Research, https://doi.org/10.1029/2001JB000884. Please note the format of such citations should be in the same style as all other references in the paper.

Web references

As a minimum, the full URL should be given and the date when the reference was last accessed. Any further information, if known (DOI, author names, dates, reference to a source publication, etc.), should also be given. Web references can be listed separately (e.g., after the reference list) under a different heading if desired, or can be included in the reference list.

Reference style

If accepted, the reference style used by the journal will be applied to the accepted article by Elsevier at the proof stage. Make sure the information in each reference is complete and correct. To see the format used by the journal, refer to a recent issue.

Journal abbreviation source
Journal names should be abbreviated according to the List of Title Word Abbreviations: http://www.issn.org/services/online-services/access-to-the-ltwa/.

Mendeley
Users of Mendeley Desktop can easily install the reference style for this journal by clicking the following link:
http://open.mendeley.com/use-citation-style/oral-surgery-oral-medicine-oral-pathology-and-oral-radiology
When preparing your manuscript, you will then be able to select this style using the Mendeley plug-ins for Microsoft Word or LibreOffice.

Artwork

Electronic artwork

Illustrations should be numbered with Arabic numerals in the order of appearance in the text and accompanied by suitable legends (see Figure Captions).

A reasonable number of halftone illustrations or line drawings will be reproduced at no cost to the author. At the editors' discretion, color illustrations may be published in grayscale with the color image available in the online edition of the Journal; elaborate tables and extra illustrations, if accepted, may also appear as supplementary material in the online edition only. Typewritten or freehand lettering on illustrations is not acceptable. All lettering must be done professionally, and letters should be in proportion to the drawings or photographs on which they appear.

Figures must be submitted in electronic figure file format. For best reproduction, images should be submitted in .tif format. Figures in .jpg format may be acceptable if they meet minimum resolution guidelines. Images embedded in programs such as PowerPoint or Word will not be accepted. Photographic images must be submitted at 300 ppi (pixels per inch) with the following dimensions: Full page 5" wide (1,500 pixels wide) or half page 3" wide (900 pixels wide). Screen capture resolutions (typically 72 ppi) will not provide adequate reproduction quality. Line-art images (charts, graphs) must be submitted at 1200 ppi with the following dimensions: Full page 5" wide (6000 pixels wide) or half page 3" wide (3600 pixels wide).

Avoid background gridlines and other formatting that do not convey information (e.g., superfluous use of 3-dimensional formatting, background shadings). All images should be cropped to show only the area of interest and the anatomy necessary to establish a regional frame of reference. Although multipart figures are not preferred, if they are used, label multipart figures with capital letters (e.g., A, B, C, etc); do not exceed nine parts to one figure. If images are to be combined in one figure, they should be the same height and magnification to facilitate reproduction.

For advice on image enhancement and annotation refer to Corl FM, et al. A five-step approach to digital image manipulation for the radiologist. *RadioGraphics* 2002;22:981-992.
For further information, please see https://www.elsevier.com/artwork.

See also *Permissions*.

Color artwork
If, together with your accepted article, you submit usable color figures then Elsevier will ensure, at no additional charge, that these figures will appear in color on the Web (e.g., ScienceDirect and other sites) in addition to color reproduction in print. For further information on the preparation of electronic artwork, please see https://www.elsevier.com/artworkinstructions. Please note: Because of technical complications that can arise by converting color figures to 'gray scale' (for the printed version should you not opt for color in print), please submit in addition usable black and white versions of all the color illustrations.

Illustration services
Elsevier's Author Services offers Illustration Services to authors preparing to submit a manuscript but concerned about the quality of the images accompanying their article. Elsevier's expert illustrators can produce scientific, technical and medical-style images, as well as a full range of charts, tables and graphs. Image 'polishing' is also available, where our illustrators take your image(s) and improve them to a professional standard. Please visit the website to find out more.

Figure captions

Each illustration must be accompanied by a legend. These should be typed double-spaced on a separate page. Keep text in the illustrations themselves to a minimum but explain all symbols and abbreviations used. If an illustration has been taken from published or copyrighted material, the legend must give full credit to the original source and accompanied by signed, written permission from the copyright holder (see *Permissions* below).

Artwork: General points

• Make sure you use uniform lettering and sizing of your original artwork.
• Embed the used fonts if the application provides that option.
• Aim to use the following fonts in your illustrations: Arial, Courier, Times New Roman, Symbol, or fonts that look similar.
• Number the illustrations according to their sequence in the text.
• Use a logical naming convention for your artwork files.
• Provide captions to illustrations to appear as a separate page in the manuscript file.
• Size the illustrations close to the desired dimensions of the printed version.
• Submit each illustration as a separate file.

A detailed guide on electronic artwork is available on our website: https://www.elsevier.com/artworkinstructions

You are urged to visit this site; some excerpts from the detailed information are given here.

Formats

Please 'Save as' or convert the images to one of the following formats (note the resolution requirements for line drawings, halftones, and line/halftone combinations given below):
EPS (or PDF): Vector drawings, embed all used fonts.
TIFF (or JPEG): Color or grayscale photographs (halftones), keep to a minimum of 300 ppi.
TIFF (or JPEG): Bitmapped (pure black & white pixels) line drawings, keep to a minimum of 1200 ppi.

Please do not:

• Supply files that are optimized for screen use (e.g., GIF, BMP, PICT, WPG); these typically have a low number of pixels and limited set of colors;
• Supply files that are too low in resolution;
• Submit graphics that are disproportionately large for the content.

Tables

Number tables consecutively using Roman numerals in accordance with their appearance in the text. Each table should be submitted as a separate file. Tables should be self-explanatory and should supplement, not duplicate, the text. All table reference citations should be repeats of numbers assigned within the text, not initial citations. A concise title should be supplied for each table. All columns should carry concise headings describing the data therein. Type all footnotes immediately below the table and define abbreviations (see also Dental Nomenclature above). If a table or any data therein have been previously published, a footnote to the table must give full credit to the original source and accompanied by signed, written permission from the copyright holder (see *Permissions* below).

Supplementary Data

To save print pages and/or shorten an article to a readable length while allowing for detailed information to be available to interested readers, authors are encouraged to provide information that is essential for the discussion of the results of the submission in the submission itself and utilize supporting information to describe experimental details and nonessential but useful information as Supplementary Material. If the manuscript is accepted for print publication, a reference to the online material will appear in the print version.
Supplementary files offer the author additional possibilities to publish supporting applications, high-resolution images, background datasets, sound clips and more. Supplementary files supplied will be published online alongside the electronic version of your article in Elsevier Web products, including ScienceDirect: http://www.sciencedirect.com. In order to ensure that your submitted material is directly usable, please provide the data in one of our recommended file formats. Authors should submit the material in electronic format together with the article and supply a concise and descriptive caption for each file. For more detailed instructions please visit our artwork instruction pages at https://www.elsevier.com/artworkinstructions.

Upload material, figures, and tables for online publication under the submission item "Supplementary Material" through the EES system. Be sure to change the description of the Supplementary Material to reflect the content; for example, Supplementary Detailed Methodology, Supplementary Figure Sx, Supplementary Table Sx.
Please order material such as Figures and Supplemental Figures separately in order of the callouts/ first mentions in the text. For example: Figure 1, Figure 2; Supplemental Figure S1, Supplemental Figure S2, etc.
In the text be sure that you add behind the reference to the supplemental material "(Supplemental Table Sx; available at [URL/link*])." *To be provided by the production department.

Data references
This journal encourages you to cite underlying or relevant datasets in your manuscript by citing them in your text and including a data reference in your Reference List. Data references should include the following elements: author name(s), dataset title, data repository, version (where available), year, and global persistent identifier. Add [dataset] immediately before the reference so we can properly identify it as a data reference. The [dataset] identifier will not appear in your published article.

Reference Style
Text: Indicate references by superscript number(s) in the text. The actual authors can be referred to, but the reference number(s) must always be given.
Example: '..... as demonstrated.3,6 Barnaby and Jones8 obtained a different result ....'
List: Number the references in the list in the order in which they appear in the text.
Examples:
Reference to a journal publication:
1. J. van der Geer, J.A.J. Hanraads, R.A. Lupton, The art of writing a scientific article, J. Sci. Commun. 163 (2010) 51–59.
Reference to a book:
2. W. Strunk Jr., E.B. White, The Elements of Style, fourth ed., Longman, New York, 2000.
Reference to a chapter in an edited book:
3. G.R. Mettam, L.B. Adams, How to prepare an electronic version of your article, in: B.S. Jones, R.Z. Smith (Eds.), Introduction to the Electronic Age, E-Publishing Inc., New York, 2009, pp. 281–304.
[dataset] 5. Oguro, M, Imahiro, S, Saito, S, Nakashizuka, T. Mortality data for Japanese oak wilt disease and surrounding forest compositions, Mendeley Data, v1; 2015. http://dx.doi.org/10.17632/xwj98nb39r.1.

Data visualization
Include interactive data visualizations in your publication and let your readers interact and engage more closely with your research. Follow the instructions here to find out about available data visualization options and how to include them with your article.

Data visualization
Include interactive data visualizations in your publication and let your readers interact and engage more closely with your research. Follow the instructions here to find out about available data visualization options and how to include them with your article.

Virtual Microscope images
The Virtual Microscope is an exciting feature that enables authors to add detailed slide images to their submissions and enables users to view the slides at their highest resolution. For more information about this feature, please see https://www.elsevier.com/authors/author-services/data-visualization/virtual-microscope

The slide images would be uploaded into a separate system; after the images are uploaded into the separate Virtual Microscope system, they will get a number, which you will then provide at the end of the related figure legends in the manuscript file: "A high resolution version of this slide is available as eSlide: VM00xxx." Replace the xxx with the assigned number.

In case you don't have a slide scanner available, we can arrange for the slides to be scanned and uploaded for you at no cost at the University of Chicago; when you contact virtualmicroscope@elsevier.com, let them know if you are interested in that option.

Imaging Data DICOM Viewer

If your paper contains images generated from DICOM data, you may receive an invitation from the Section editor(s) after submission inviting you to complement your online article by providing volumetric radiological data of a case, a specific example, or multiple datasets in DICOM format. Readers will be able to interact, adjust, display, and view the DICOM data using an interactive viewer embedded within your article. Specifically, the viewer will enable users to explore the DICOM data as 2D orthogonal MPR series, 3D volume rendering and 3D MIP. Specific enhancements include zoom, rotate and pan 3D reconstructions, section through the volume, and change opacity and threshold level. Each DICOM dataset will have to be zipped in a folder and uploaded to the online submission system via the "DICOM dataset" submission category. The recommended size of a single uncompressed dataset is 200 MB or less. Please provide a short informative description for each dataset by filling in the 'Description' field when uploading each ZIP file. Note: All datasets will be available for download from the online article on ScienceDirect, so please ensure that all DICOM files are **anonymized** before submission. For more information see: https://www.elsevier.com/about/content-innovation/radiological-data

Video

OOOO encourages submission of content-rich video files that enhance clinical relevance/significance. For example, we prefer video clips with content in terms of demonstration of the technique or procedure discussed in the work and/or more details about the methodology.

Elsevier accepts video material and animation sequences to support and enhance your scientific research. Authors who have video or animation files that they wish to submit with their article are strongly encouraged to include links to these within the body of the article. This can be done in the same way as a figure or table by referring to the video or animation content and noting in the body text where it should be placed. All submitted files should be properly labeled so that they directly relate to the video file's content. In order to ensure that your video or animation material is directly usable, please provide the file in one of our recommended file formats with a preferred maximum size of 150 MB per file, 1 GB in total. Video and animation files supplied will be published online in the electronic version of your article in Elsevier Web products, including ScienceDirect.

Please supply a legend and a 'still' with each video file: you can choose any frame from the video or animation or make a separate image. These will be used instead of standard icons and will personalize the link to your video data. For more detailed instructions please visit our video instruction pages. Note: since video and animation cannot be embedded in the print version of the journal, please provide text for both the electronic and the print version for the portions of the article that refer to this content.

Permissions

Upload written permissions from the copyright holder to republish previously published material. Authors are responsible for obtaining and uploading any needed permissions and for clearly and completely identifying any overlapping material and/or quoted or paraphrased passages with proper attribution in the text to avoid plagiarism (including self-plagiarism). The Permissions FAQ for Authors is available at https://www.elsevier.com/authors/permission-seeking-guidelines-for-elsevier-authors. For assistance, please contact Elsevier's Permissions Helpdesk: +1-800-523-4069 x 3808; +1-215-239-3805; permissionshelpdesk@elsevier.com

Written, signed permission(s) from the patient or legal guardian is/are required for publication of recognizable photographs. Clearly state in your cover letter that patient consent has been obtained and has been uploaded under "Permission/s." If it is impossible to obtain a consent form, the image(s) must be removed or sufficiently cropped to the area of interest only or otherwise changed so the patient cannot be recognized. However, blurring or placing bars over the eyes is no longer acceptable to eliminate the need for a signed consent form. The restrictions for photos have become very strict. For more information, refer to https://www.elsevier.com/about/company-information/policies/patient-consent.

Letters to the Editor

Letters to the Editor should be a succinct comment pertaining to a paper(s) published in the Journal within the past year or to related topics. Provide a unique title for the Letter on the title page with complete contact information for the author(s). Double-space the text of the Letter. References,

including reference to the pertinent article(s) in the Journal, should conform to style for manuscripts (see *References*). If accepted, the author(s) of the pertinent article(s) may be contacted to prepare a response to the comment.

Announcements

Announcements must be received by the Editorial Office at least 10 weeks before the desired month of publication. Items published at no charge include those received from a sponsoring society of the Journal; courses and conferences sponsored by state, regional, or national dental organizations; and programs for the dental profession sponsored by government agencies. All other announcements selected for publication by the Editor carry a charge of $60 US, and the fee must accompany the request to publish.

Research data

This journal encourages and enables you to share data that supports your research publication where appropriate, and enables you to interlink the data with your published articles. Research data refers to the results of observations or experimentation that validate research findings. To facilitate reproducibility and data reuse, this journal also encourages you to share your software, code, models, algorithms, protocols, methods and other useful materials related to the project.

Below are a number of ways in which you can associate data with your article or make a statement about the availability of your data when submitting your manuscript. If you are sharing data in one of these ways, you are encouraged to cite the data in your manuscript and reference list. Please refer to the "References" section for more information about data citation. For more information on depositing, sharing and using research data and other relevant research materials, visit the research data page.

Data linking

If you have made your research data available in a data repository, you can link your article directly to the dataset. Elsevier collaborates with a number of repositories to link articles on ScienceDirect with relevant repositories, giving readers access to underlying data that gives them a better understanding of the research described.

There are different ways to link your datasets to your article. When available, you can directly link your dataset to your article by providing the relevant information in the submission system. For more information, visit the database linking page.

For supported data repositories a repository banner will automatically appear next to your published article on ScienceDirect.

In addition, you can link to relevant data or entities through identifiers within the text of your manuscript, using the following format: Database: xxxx (e.g., TAIR: AT1G01020; CCDC: 734053; PDB: 1XFN).

Mendeley Data

This journal supports Mendeley Data, enabling you to deposit any research data (including raw and processed data, video, code, software, algorithms, protocols, and methods) associated with your manuscript in a free-to-use, open access repository. During the submission process, after uploading your manuscript, you will have the opportunity to upload your relevant datasets directly to *Mendeley Data*. The datasets will be listed and directly accessible to readers next to your published article online.

For more information, visit the Mendeley Data for journals page.

Data statement

To foster transparency, we encourage you to state the availability of your data in your submission. This may be a requirement of your funding body or institution. If your data is unavailable to access or unsuitable to post, you will have the opportunity to indicate why during the submission process, for example by stating that the research data is confidential. The statement will appear with your published article on ScienceDirect. For more information, visit the Data Statement page.

Submission Checklist

The following list will be useful during the final checking of an article prior to sending it to the journal for review. Please consult this Guide for Authors for further details of any item.

Ensure that the following items are present:

__ Letter of submission, to include disclosure of any previous publications or submissions with any overlapping information
__ Statement of clinical relevance (uploaded separately)
__ Title page
__ Title of article
__ Full names(s), academic degree(s), affiliation(s) and titles of author(s)
__ Author to whom correspondence, proof, and reprint requests are to be sent, including address and business and home telephone numbers, fax number, and e-mail address
__ Any conflict of interest statement(s), disclosure(s), and/or financial support information, including donations
__ Word count for the abstract (if relevant to article type), a complete manuscript word count (to include body text and figure legends), number of references, and number of figures/tables
__ Structured abstract (double-spaced as part of manuscript file), as relevant to article type
__ Article proper (double-spaced)
__ Statement of IRB review and compliance with Helsinki Declaration (stated in Methods section of manuscript, as relevant)
__ References (double-spaced on a separate page of the manuscript file)
__ Figure legends (double-spaced, on a separate page of the manuscript file)
__ Tables (double-spaced, uploaded separately as word processing [eg, .doc] files)
__ Illustrations, properly formatted (uploaded as separate files)
__ Video/computer graphics, properly formatted (uploaded as separate files)
__ Signed permission to reproduce any previously published material, in all forms and media (scanned in as a file and uploaded as Permission)
__ Signed permission to publish photographs of identifiable persons from the individual or legal guardian specifying permission in all forms and media (scanned in as a file and uploaded as Permission)
For any further information please visit our customer support site at https://service.elsevier.com.

AFTER ACCEPTANCE

Proofs
Corresponding authors will receive an e-mail with a link to our online proofing system, allowing annotation and correction of proofs online. The environment is similar to MS Word: in addition to editing text, you can also comment on figures/tables and answer questions from the Copy Editor. Web-based proofing provides a faster and less error-prone process by allowing you to directly type your corrections, eliminating the potential introduction of errors. If preferred, you can still choose to annotate and upload your edits on the PDF version. All instructions for proofing will be given in the e-mail we send to authors, including alternative methods to the online version and PDF. We will do everything possible to get your article published quickly and accurately. Please use this proof only for checking the typesetting, editing, completeness and correctness of the text, tables and figures. Significant changes to the article as accepted for publication will only be considered at this stage with permission from the Editor. It is important to ensure that all corrections are sent back to us in one communication. Please check carefully before replying, as inclusion of any subsequent corrections cannot be guaranteed. Proofreading is solely your responsibility.

AUTHOR INQUIRIES

Visit the Elsevier Support Center to find the answers you need. Here you will find everything from Frequently Asked Questions to ways to get in touch.
You can also check the status of your submitted article or find out when your accepted article will be published.

© Copyright 2018 Elsevier | https://www.elsevier.com

IV. CONCLUSÃO

IV. CONCLUSÃO

1) Após a separação da osteotomia sagital do ramo mandibular, a possibilidade do nervo alveolar inferior aderir ao segmento proximal aumenta na medida em diminui a distância do canal mandibular à superfície interna da cortical bucal nas regiões dos segundos e terceiros molares.

2) A possibilidade do nervo alveolar inferior aderir ao segmento proximal após o procedimento de separação da osteotomia sagital do ramo mandibular é ampliada conforme aumenta a distância do canal mandibular à superfície interna da cortical lingual na região do segundo molar inferior.

3) Em mandíbulas estreitas, é maior a possibilidade do nervo alveolar inferior apresentar-se aderido ao segmento proximal após a separação da osteotomia sagital do ramo mandibular.

4) O estudo não encontrou resultados significantes na análise da proporção de osso cortical e medular e da densidade óssea;

5) Na comparação entre gêneros, os pacientes do sexo masculino apresentaram maiores médias de distância do canal mandibular à cortical bucal quando comparadas a pacientes do sexo feminino.

V. BIBLIOGRAFIA

V. BIBLIOGRAFIA

1 Tsuji Y, Muto T, Kawakami J, Takeda S. Computed tomographic analysis of the position and course of the mandibular canal: relevance to the sagittal split ramus osteotomy. Int J Oral Maxillofac Surg. [Internet] 2005 [cited by 2020 may 13]; 34: 243–246. DOI: 10.1016/j.ijom.2004.06.001.

2 Aizenbud D, Ciceu C, Hazan-Molina H, Abu-El-Naaj I. Relationship between inferior alveolar nerve imaging and neurosensory impairment following bilateral sagittal split osteotomy in skeletal class III cases with mandibular Prognathism. Int J Oral Maxillofac Surg. [Internet] 2012 [cited by 2020 apr 14]; 41: 461–468. DOI: 10.1016/j.ijom.2011.10.024.

3 Young-Kyun K, Su-Gwan K, Jong-Hwa K. Altered Sensation After Orthognathic Surgery. J Oral Maxillofac Surg. [Internet] 2011 [cited by 2020 feb 15]; 69: 893-898. DOI: 10.1016/j.joms.2010.10.025.

4 Sousa CS, Turrinil RNT. Complications in orthognatic surgery: A comprehensive review. J Oral Maxillofac Surg Med Pathol. [Internet] 2012 [cited by 2020 feb 20]; 24: 67-74. DOI: 10.1016/j.ajoms.2012.01.014.

5 Yoshioka I, Tanaka T, Khana A, Habu M, Kito S, Kodama, M *et al*. Relationship Between Inferior Alveolar Nerve Canal Position at Mandibular Second Molar in Patients With Prognathism and Possible Occurrence of Neurosensory Disturbance After Sagittal Split Ramus Osteotomy. J Oral Maxillofac Surg. [Internet] 2010 [cited by may 16]; 68: 3022-3027. DOI: 10.1016/j.joms.2009.09.046.

6 Ylikontiola L, Kinnunen J, Laukkanen P *et al*. Prediction of recovery from neurosensory deficit after bilateral sagittal split osteotomy**.** J Oral Surg Oral Med Oral Pathol Oral Radiol Endod. [Internet] 2000 [cited by 2020 mar 16]; 90: 275-81. DOI: 10.1067/moe.2000.108920.

7 Hanzelka T, Foltán R, Pavlíkova G, Horka E, Sedy J. The role of intraoperative positioning of the inferior alveolar nerve on postoperative paresthesia after bilateral sagittal split osteotomy of the mandible: prospective clinical study. Int J Oral Maxillofac Surg. [Internet] 2011 [cited by 2020 mar 8]; 40: 901–906. DOI: 10.1016/j.ijom.2011.04.002.

8 Panula K, Finne K, Oikarinen K. Neurosensory deficits after bilateral sagittal split ramus osteotomy of the mandible-influence of soft tissue handling medial to the ascending ramus. Int J Oral Maxillofac Surg. [Internet] 2004 [cited by 2020 apr 12]; 33: 543–548. DOI: 10.1016/j.ijom.2003.11.005.

9 Teerijoki-Oksa T, Jaaskelainen SK, Forssell K, Forssell H, Vahatalo K, Tammisalo T *et al*. Risk factors of nerve injury during mandibular sagittal split osteotomy. Int J Oral Maxillofac Surg. [Internet] 2002 [cited by 2020 may 18]; 31: 33–39. DOI: 10.1054/ijom.2001.0157.

10 Fridrich KL, Holton TJ, Pansegrau KJ, Buckley MJ. Neurosensory recovery following the mandibular bilateral sagittal split osteotomy. J Oral Maxillofac Surg. [Internet] 1995 [cited by 2020 may 14]; 53: 1300–1306. DOI: 10.1016/0278-2391(95)90588.

11 Noleto JW, Marchiori E, Silveira HM. Evaluation of Mandibular Ramus Morphology Using Computed Tomography in Patients With Mandibular Prognathism and Retrognathia: Relevance to the Sagittal Split Ramus Osteotomy. J Oral Maxillofac Surg. [Internet] 2010 [cited by 2020 apr 19]; 68: 1788-1794. DOI: 10.1016/j.joms.2009.12.028.

12 Yu IH, Wong YK. Evaluation of mandibular anatomy related to sagittal split ramus osteotomy using 3-dimensional computed tomography scan images. Int J Oral Maxillofac Surg. [Internet] 2008 [cited by 2020 apr 17]; 37: 521–528. DOI: 10.1016/j.ijom.2008.03.003.

13 Trauner R, Obwegeser H. The surgical correction of mandibular prognathism and retrognathia with consideration of genioplasty. I. Oral Surg Oral Med Oral Pathol. [Internet] 1957 [cited by 2020 apr 6]; 10: 677-689. DOI: 10.1016/s0030-4220(57)80041-3.

14 Dal Pont G. Retromolar osteotomy for the correction of prognathism. J Oral Surg. [Internet] 1961 [cited by 2020 mar 4]; 19: 42-47. Available from: https://pubmed.ncbi.nlm.nih.gov/13719390/. PMID: 13719390.

15 Hunsuck EE. A modified intraoral sagittal splitting technic for correction of mandibular prognathism. J Oral Surg. [Internet] 1968 [cited by 2020 mar 10]; 26: 250-254. Available from: https://pubmed.ncbi.nlm.nih.gov/5237786/. PMID: 5237786.

16 Ylikontiola L, Moberg K, Huumonen S, Soikkonen K, Oikarinen K. Comparison of three radiographic methods used to locate the mandibular canal in the buccolingual direction before bilateral sagittal split osteotomy. Oral Surg Oral Med Oral Pathol Oral Radiol Endod [Internet] 2002 [cited by 2020 feb 12]; 93: 736-42. DOI: 10.1067/moe.2002.122639.

17 Mensink G, Gooris PJJ, Bergsma JE, van Hooft E, van Merkesteyn JPR. Influence of BSSO surgical technique on postoperative inferior alveolar nerve hypoesthesia: A systematic review of the literature. J Cranio-Maxillofac Surg. [Internet] 2014 [cited by 2020 feb 29]; 42: 976-982. DOI: 10.1016/j.jcms.2014.01.019.

18 Yamamoto R, Nakamura A, Ohno K, Michi K. Relationship of the Mandibular Canal to the Lateral Cortex of the Mandibular Ramus as a Factor in the Development of Neurosensory Disturbance After Bilateral Sagittal Split Osteotomy. J Oral Maxillofac Surg. [Internet] 2002 [cited by 2020 mar 12]; 60: 490-495. DOI: 10.1053/joms.2002.31843.

19 Wittwer G, Adeyemo WL, Beinemann J, Juergens P. Evaluation of risk of injury to the inferior alveolar nerve with classical sagittal split osteotomy technique and proposed alternative surgical techniques using computer-assisted surgery. Int J Oral Maxillofac Surg. [Internet] 2012 [cited by 2020 mar 15]; 41: 79–86. DOI: 10.1016/j.ijom.2011.08.001.

20 Huang CS, Syu JJS, Ko EWC, Chen YR. Quantitative Evaluation of Cortical Bone Thickness in Mandibular Prognathic Patients With Neurosensory Disturbance After Bilateral Sagittal Split Osteotomy. J Oral Maxillofac Surg. [Internet] 2013 [cited by 2020 mar 25]; 71: 2153.e1-2153.e10. DOI: 10.1016/j.joms.2013.08.004.

21 Levine MH, Goddard AL, Dodson TB. Inferior Alveolar Nerve Canal Position: A Clinical and Radiographic Study. J Oral Maxillofac Surg. [Internet] 2007 [cited by 2020 apr 03]; 65: 470-474. DOI: 10.1016/j.joms.2006.05.056.

22 Yoshioka I, Tanaka T, Khaal A, Habu M, Kito S, Kodama M *et al*. Correlation of mandibular bone quality with neurosensory disturbance after sagittal split ramus osteotomy. British J Oral Maxillofac Surg. [Internet] 2011 [cited by 2020 jun 1]; 49: 552–556. DOI: 10.1016/j.bjoms.2010.09.014.

23 Yoshioka I, Tanaka T, Habu M, Oda M, Kodama M, Kito S *et al*. Effect of bone quality and position of the inferior alveolar nerve canal in continuous, long-term, neurosensory disturbance after sagittal split ramus osteotomy. J Cranio-Max-Fac Surg. [Internet] 2012 [cited by 2020 apr 8]; 40: 178-183. DOI: 10.1016/j.jcms.2011.09.003.

24 Yamauchi K, Takahashi T, Kaneuji T, Nogami S, Yamamoto N, Miyamoto I *et al*. Risk Factors for Neurosensory Disturbance After Bilateral Sagittal Split Osteotomy Based on Position of Mandibular Canal and Morphology of Mandibular Angle. J Oral Maxillofac Surg. [Internet] 2012 [cited by 2020 apr 15]; 70: 401-406. DOI: 10.1016/j.joms.2011.01.040.

25 Kuroyanagi N, Shimozato K. Prediction of neurosensory alterations after sagital split ramus osteotomy. Int. J. Oral Maxillofac. Surg. [Internet] 2013 [cited by 2020 may 6]; 42: 814–822. DOI: 10.1016/j.ijom.2012.11.016.

26 Westermark A, Bystedt H, von Konow L. Inferior alveolar nerve function after sagittal split osteotomy of the mandible: correlation with degree of intraoperative nerve encounter and other variables in 496 operations. British J Oral Maxillofac Surg. [Internet] 1998 [cited by 2020 mar 20]; 36: 429-433. DOI: 10.1016/s0266-4356(98)90458-2.

27 Thygesen TH, Bardow A, Helleberg M, Norholt SE, Jensen J, Svensson P. Risk Factors Affecting Somatosensory Function After Sagittal Split Osteotomy. J Oral Maxillofac Surg. [Internet] 2008 [cited by 2020 mar 27]; 66: 469-474. DOI: 10.1016/j.joms.2007.06.666.

28 Bruckmoser E, Bulla M, Alacamlioglu Y, Steiner I, Watzke IM. Factors influencing neurosensory disturbance after bilateral sagittal split osteotomy: retrospective analysis after 6 and 12 months. Oral Surg Oral Med Oral Pathol Oral Radiol. [Internet] 2013 [cited by 2020 apr 10]; 115: 473-482. DOI: 10.1016/j.oooo.2012.08.454.

29 Ueki K, Sotobori M, Ishihara Y, Iguchi R, Kosaka A, Ikawa H *et al.* Evaluation of factors affecting recovery period in lower lip hypoesthesia after sagittal split ramus osteotomy in mandibular prognathism patients. J Cranio-Max-Fac Surg. [Internet] 2014 [cited by 2020 apr 20]; 42: 1748-1752. DOI: 10.1016/j.jcms.2014.06.010.

30 Yoshida T, Nagamine T, Kobayashi T, Michimi N, Nakajima T, Sasakura H *et al*. 2Impairment of the Inferior Alveolar Nerve after Sagittal Split Osteotomy. J. Cranio-Max.-Fac. Surg. [Internet] 1989 [cited by 2020 may 10]; 17: 271-278. DOI: 10.1016/s1010-5182(89)80095-2.

31 Rich J, Golden BA, Phillips C. Systematic review of preoperative mandibular canal position as it relates to postoperative neurosensory disturbance following the sagittal split ramus osteotomy. Int. J. Oral Maxillofac. Surg. [Internet] 2014 [cited by 2020 may 12]; 43: 1076–1081. DOI: 10.1016/j.ijom.2014.03.020.

32 Simonton JD, Azevedo B, Schindler WG, Hargreaves KM. Age- and Gender-related Differences in the Position of the Inferior Alveolar Nerve by Using Cone Beam Computed Tomography. J Endod. [Internet] 2009 [cited by 2020 apr. 20]; 35: 944–949. DOI: 10.1016/j.joen.2009.04.032.

33 Tamas F. Position of the mandibular canal. Int J Oral Maxillofac Surg. [Internet] 1987 [cited by 2020 apr. 25]; 16: 65-9. DOI: 10.1016/s0901-5027(87)80032-2.

34 Gowgiel JM. The position and course of the mandibular canal. J Oral Implantol. [Internet] 1992 [cited by 2020 apr. 28]; 8: 383-5. Available from: https://pubmed.ncbi.nlm.nih.gov/1298823/.

35 Wolford M, Bennett MA, Ragerty CG. Modification of the mandibular ramus sagittal split osteotomy. Oral Surg. Oral Med. Oral Pathol. [Internet] 1987 [cited by 2020 may 01]; 64: 46-55. DOI: 10.1016/0030-4220(87)90080-6.

36 Brusati R, Fiamminghi L, Sesenna E, Gazzotti A. Functional Disturbances of the Inferior Alveolar Nerve after Sagittal Osteotomy of the Mandibular Ramus: Operating Technique for prevention**.** J. Max. Fac. Surg. [Internet] 1981 [cited by 2020 may 20]; 9: 123-125. DOI: https://doi.org/10.1016/S0301-0503(81)80028-8.

VI. ANEXOS

VI. ANEXOS

6.1 Anexo A – Comprovação de Submissão do Artigo Científico

Oral Surgery, Oral Medicine, Oral Pathology and Oral Radiology

Evaluation of the Anatomic Position of the Mandibular Canal in Relation to the Segments of Mandibular Sagittal Split Ramus Osteotomy

--Manuscript Draft--

Manuscript Number:	
Article Type:	Original Research Article
Keywords:	Mandibular sagittal split ramus osteotomy; Mandibular Nerve; Orthognathic Surgery
Corresponding Author:	Adriano Rocha Germano, DDS, MSc, Ph.D. Universidade Federal do Rio Grande do Norte Natal, Rio Grande do Norte BRAZIL
First Author:	Adriano Rocha Germano, DDS, MSc, Ph.D.
Order of Authors:	Adriano Rocha Germano, DDS, MSc, Ph.D.
	Salomão Israel, DDS, MS
	Alessandro Costa da Silva, DDS, MS, PhD
	Susana Silva, DDS, MS, PhD
	Victor Diniz Borborema dos Santos, DDS, MS
	José Sandro Pereira da Silva, DDS, MS, PhD
Abstract:	Purpose This study evaluated the relationship between nerve location through CT scan relationship and intraoperative nerve entrapment after BSSO. Material and Methods 20 CT scans were evaluated in patients facial deformities who underwent to BSSO. The distance from the mandibular canal to the internal surface of the buccal and lingual cortical bone, mandibular thickness, bone density and proportion of medullary and cortical bone in 3 regions were evaluated. During the intraoperative period, the segment to which the nerve remained adhered after performing BSSO was analyzed and the data correlated. Results The distance from the mandibular canal to the buccal cortical bone showed a mean of 2.6 mm when the nerve was adhered to the distal segment and mean of 0.7 mm when the nerve was adhered to the proximal segment. The thickness was 11.2 mm and 9.8 mm when the nerve was adhered the distal the proximal segments respectively. Mandibular thickness, distance from the mandibular canal to the buccal and lingual cortical were statistically related to intraoperative nerve entrapment (p <0,05). Conclusion Narrow jaws and the distance from the mandibular canal to buccal cortical bone less then 2 mm increases the risk of the nerve entrapment in BSSO.
Suggested Reviewers:	
Opposed Reviewers:	

Powered by Editorial Manager® and ProduXion Manager® from Aries Systems Corporation

6.2 Anexo B – Declaração de cumprimento antiplágio

UNIVERSIDADE CATÓLICA PORTUGUESA

VISEU

Declaração de cumprimento anti - plágio.

Eu, SUSANA ANA FERNANDES MACIAGO DA SILVA, orientador da monografia intitulada EVALUATION OF THE ANATOMIC POSITION OF THE MANDIBULAR CONDYLE IN RELATION TO THE SEGMENTS OF MANDIBULAR SAGITTAL SPLIT RAMUS OSTEOTOMY, confirmo que o trabalho apresentado foi analisado na plataforma *"Turnitin"* e apresenta um índice de similaridade 30 % cumprindo os requisitos anti plágio definidos.

Viseu, 26 / 06 / 2020

(O orientador da monografia)

6.3 Anexo B – Declaração do Comitê de Ética em Pesquisa

HOSPITAL UNIVERSITÁRIO
ONOFRE LOPES-HUOL/UFRN

PARECER CONSUBSTANCIADO DO CEP

DADOS DO PROJETO DE PESQUISA

Título da Pesquisa: A relação entre a posição pré-operatória do nervo alveolar inferior e a parestesia, na osteotomia sagital do ramo mandibular

Pesquisador: Adriano Rocha Germano

Área Temática:

Versão: 2

CAAE: 09917313.2.0000.5292

Instituição Proponente: Hospital Universitário Onofre Lopes

Patrocinador Principal: Financiamento Próprio

DADOS DO PARECER

Número do Parecer: 379.988

Data da Relatoria: 23/08/2013

Apresentação do Projeto:

O presente projeto está bem estruturado e demonstra os aspectos metodológicos bem correlacionados aos objetivos centrais do trabalho. Sendo indicadas realizações de: Cirurgia eletiva sob anestesia geral; Responderá ao questionário padronizado da pesquisa; Será submetido a tomografia computadorizada da mandíbula no pré-operatório e será submetido a testes de sensibilidade na região mentoniana(queixo);

Objetivo da Pesquisa:

O objetivo deste trabalho é avaliar a incidência de alteração sensitiva associada ao nervo alveolar inferior após osteotomia sagital do ramo mandibular, aplicando testes diagnósticos específicos e considerando a posição tridimensional do nervo alveolar inferior no pré-operatório e a posição encontrada no trans-operatório.

Avaliação dos Riscos e Benefícios:

Os riscos da pesquisa são mínimos, já que os procedimentos os dados serão coletados a partir da aplicação de questionário padronizado da pesquisa para análise da anatomia do ramo mandibular bilateral e a avaliação subjetiva e objetiva da função do NAI.

Comentários e Considerações sobre a Pesquisa:

As pendências foram sanadas.

Endereço: Avenida Nilo Peçanha, 620 - 3¿subsolo
Bairro: Petrópolis **CEP:** 59.012-300
UF: RN **Município:** NATAL
Telefone: (84)3342-5003 **Fax:** (84)3202-3941 **E-mail:** cep_huol@yahoo.com.br